

## A Novel Application of the Lotus Petal Flap in High-Risk Perineal Urethroscopy: Principles and Outcomes

Daniel J. Reilly,<sup>1</sup> Eric K. Sham,<sup>1</sup> Justin B. L. Chee<sup>1</sup> and Ajay Chauhan<sup>1</sup>

<sup>1</sup> MURAC Health  
Melbourne, Victoria, Australia

OPEN ACCESS

### Correspondence

**Name:** Ajay Chauhan

**Address:**

MURAC Health  
Melbourne VIC 3002  
Australia

**Email:** [ajay.chauhan@murachealth.org](mailto:ajay.chauhan@murachealth.org)

**D. J. Reilly** MBBS BMedSc; **E. K. Sham** MBBS; **J. B. L. Chee** MBBS FRACS; **A. Chauhan** MBBS FRACS

### Citation

Reilly DJ, Sham EK, Chee JBL, Chauhan A. A novel application of the lotus petal flap in high-risk perineal urethroscopy: principles and outcomes. *Australasian Journal of Plastic Surgery*. 2018; 1(1): 169-175.

Accepted for publication: 8 December 2017.

**Copyright** © 2018. Authors retain their copyright in the article. This is an open access article distributed under the Creative Commons Attribution License, which permits unrestricted use, distribution, and reproduction in any medium, provided the original work is properly cited.

### Abstract

**Introduction:** Perineal urethroscopy is a valuable technique in the management of complex anterior urethral strictures, as well as following penectomy or urethrectomy. Traditional techniques that employ perineal or scrotal skin flaps have documented failure rates of up to 30%. Current techniques for salvage have only modest success, leaving patients few options other than permanent suprapubic catheter or cystectomy and ileal conduit formation.

**Results:** We present a new method of perineal urethroscopy using perforator-based lotus petal flaps in cases which were high risk or unsuitable for traditional perineal urethroscopy techniques, or where traditional strategies had failed. All patients demonstrated continent voiding at a minimum of 22 months follow-up, with patency confirmed by flexible cystoscopy. No complications were encountered.

**Conclusion:** Utilisation of lotus petal flaps in high-risk cases of perineal urethroscopy will lead to significant improvements in patient outcomes. The availability of larger amounts of soft tissue coverage will obviate the need for compromise on either resection of involved urethra, or calibre and inset of urethroscopy. This will subsequently minimise the rates of failure, reduce the requirement for urinary diversion procedures and lead to improved quality of life.

**Key words:** Perforator Flap; Local Flap; Perineal Reconstruction; Perineal Urethroscopy; Genitourinary Reconstruction

## Introduction

Perineal urethroscopy (PU) is a valuable technique in the management of anterior urethral strictures. It is indicated in situations where urethroplasty is unable to be performed; as a salvage for failed urethroplasty, or as the first step of a staged urethroplasty.<sup>1</sup> It is also utilised following penectomy or urethrectomy to avoid the need for a permanent suprapubic catheter.<sup>2</sup> PU allows patients to maintain continent voiding, and has been shown to maintain patient quality of life.<sup>3</sup>

Traditional operative techniques, as described by Johanson and Blandy, incorporate perineal and scrotal skin flaps to allow the urethra to be mobilised without excessive tension, minimising rates of stenosis.<sup>4, 5</sup>

Failure of PU has been defined as any patient requiring post-operative instrumentation, and the reported rate of failure ranges from 21.6-30%.<sup>3, 6-8</sup>

Multiple factors can contribute to failure of perineal urethrostomies. These include recurrence of the underlying pathology (such as urethral cancer or lichen sclerosus), inadequate debridement of involved proximal urethra, wound infection, or excessive tension at the anastomosis.<sup>9</sup> Radiotherapy,<sup>7</sup> prior failed urethroplasty, and a traumatic or infective stricture aetiology<sup>3</sup> have been shown to increase risk of PU failure.

Currently used salvage techniques for failed PU include repeated local random-pattern flaps<sup>10, 11</sup> and buccal mucosal<sup>12</sup> or split-thickness skin grafts,<sup>9</sup> with only modest success being reported. The only alternative after failed revision PU is urinary diversion, such as supra-pubic catheterisation or ileal conduit formation.<sup>9</sup>

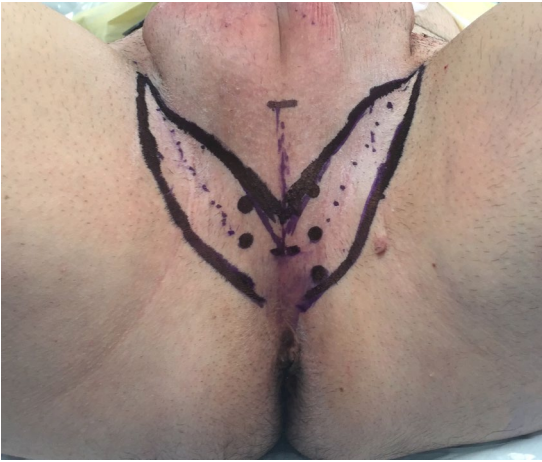
Our aim was to develop a technique that enabled creation of the urethroscopy to an adequate calibre using vascularised tissue based on known regional perforator anatomy, sufficient to permit tension-free closure, in cases that would be high risk or unsuitable for traditional PU methods.

## Methods

Following general anaesthesia, the patient is placed in the lithotomy position. Perforating vessels of the internal pudendal system are identified using hand-held Doppler ultrasound. Prophylactic intravenous antibiotics are administered prior to incision, and the urethra is debrided to healthy viable tissue. The proximal urethra is spatulated and absorbable stay sutures are inserted.

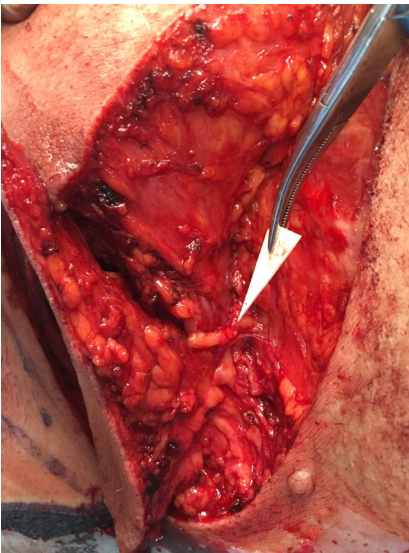
The distance from the perineal skin to the urethra is measured, and the lotus petal flap is marked incorporating the previously identified perforating vessels (Fig. 1).

Reilly, Sham, Chee and Chauhan



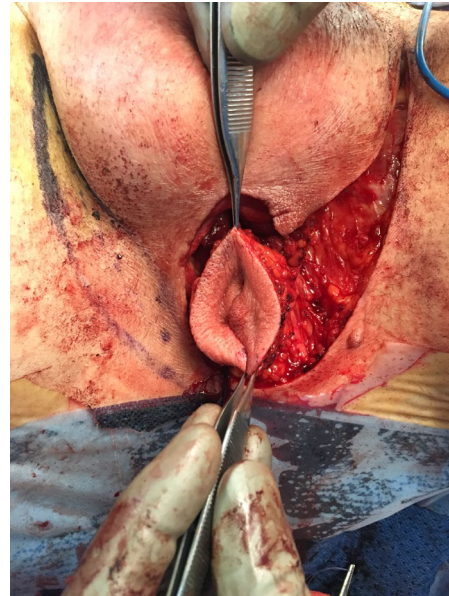
**Fig. 1** Pre-operative markings following perforator identification using hand-held Doppler ultrasound.

The initial incision is made and then the flap is raised in a supra-fascial plane from distal to proximal in the manner previously described, with identification and dissection of the perforating vessels (Fig. 2).



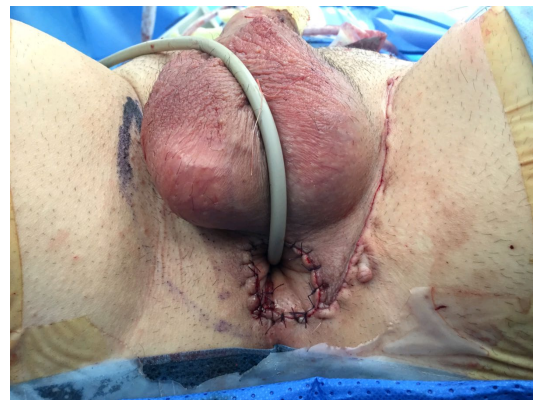**Fig. 2** Flap elevation with identification of perforator.

The skin paddle is completely islanded if desired or may be left with a posterior skin bridge intact (to help direct the flow of urine). If islanded, the flap may be completely tubularised to form the full circumference of a neo-urethra, in cases where there is extreme shortage of native urethral length (Fig. 3).



**Fig. 3** Isolated and tubularised lotus petal flap.

The donor site is closed in layers over a suction drain, and the flap is inset to form the urethrostomy using absorbable sutures (Fig. 4). A Foley catheter is inserted, and remains in place for 5 days post-operatively. Drains are usually removed on the first post-operative day. There are no specific positional nursing requirements.



**Fig. 4** Flap inset with primary closure of donor site.

## Results

To date, this technique has been used in three patients through our institution. Their cases are summarised in Table 1. All patients have demonstrated continent voiding with a minimum

follow-up of 22 months, with no requirement for instrumentation or revision. All patients were assessed with flexible cystoscopy between 6 and 9 months post-operatively to confirm patency.

**Table 1.** Summary of cases (PU – perineal urethrostomy; SCC – squamous cell carcinoma; LPF – lotus petal flap)

Case	Age	Indication	Technique	Follow-Up
1	64M	Failed PU following Fourniere's gangrene	Unilateral non-islanded LPF	29 months
2	87M	Revision of stenotic PU following scrotal SCC	Unilateral non-islanded LPF	22 months
3	52M	Primary PU following urethrectomy to membranous urethra for SCC	Unilateral islanded and tubularised LPF	24 months

## Discussion

Soft tissue defects of the perineum have long represented a complex challenge for the reconstructive surgeon. Multiple reconstructive modalities have been described for wounds of this region, including regional myocutaneous flaps and local random-pattern or axial skin flaps.<sup>13</sup> More recent developments have included perforator-based flaps.<sup>14</sup>

The lotus-petal flap was first described in 1996 for use in the reconstruction of vulvo-vaginal defects.<sup>15</sup> Since that initial description, it has been used in a range of indications for wounds of the perineum, including scrotal and perianal defects.<sup>16, 17</sup> In their initial description, Yii and Niranjani advocated elevating the flap with the deep fascia and identifying the perforating vessels. Warriar *et al.* have described an adipocutaneous

modification of the flap that does not involve identification of the perforators.<sup>18</sup>

A related flap, the pudendal thigh flap, has previously been used in the reconstruction of traumatic posterior urethral strictures.<sup>19</sup> However, to our knowledge this is the first report of local perforator-based flaps for perineal urethrostomy.

Previous authors have described multiple techniques to address failure of perineal urethrostomies. Many patients undergo repeated dilatations of the stricture, but this technique does not address the underlying pathology and is usually only a temporary solution. Revision PU with buccal mucosal grafts have been described, but this is limited by the availability of donor tissue.<sup>12</sup>

The '7-flap' technique described by French *et al.* is a recent technique aimed at minimising failure in PU.<sup>10</sup> It utilises a local random-pattern flap that presents several advantages over the traditional perineal and scrotal flaps of the Johanson and Blandy techniques, including the ability to design the skin flap once the defect has already been created. However, given its dimensions and the random nature of its vascular supply, there remains a significant risk of wound tension and flap necrosis, particularly in high-risk patients. It also relies on local tissue that may not be free of the underlying disease process, such as radiotherapy damage or lichen sclerosus.

Lumen *et al.* have described the use of split-thickness skin grafts (SSG) for revision PU in a single case of urethral SCC.<sup>9</sup> However, most revision PU cases involve poorly vascularised wound beds and fibrosis following previous surgery, infection or irradiation. Secondary contracture of SSGs can lead to a total failure of the PU due to stenosis.

The lotus petal flap confers numerous advantages over the existing reconstructive options. It represents a thin, pliable flap with a reliable vascular pedicle over a rich anastomotic network that lies outside the 'zone of injury' of disease. It is possible to orient the flap donor site in a number of ways, allowing reliable modification to suit the requirements of a particular defect. The donor site is well tolerated. Bilateral flaps can be reliably raised in cases where there is a need for additional soft tissue. In cases where insufficient proximal urethral stump exists for traditional PU, the lotus petal flap technique offers a solution by bridging the urethral defect and the perineal skin with a vascularised tube. This is especially important in urethral cancer cases where a very proximal amputation is required for oncological clearance, and which would usually mandate more proximal urinary diversion.

The lotus petal design allows for both partial and total circumferential inset for formation of the PU. The latter is achieved either by utilising two (bilateral) flaps or a completely islanded and tubularised single flap (as demonstrated in case 3). There are myriad alternative configurations possible, including separate flaps for the PU and perineal resurfacing when required.

There are several potential disadvantages to the use of the lotus petal flap in PU. Perforator flap dissection can be technically challenging and should only be performed by an experienced reconstructive surgeon. The vascular pedicle can be at risk from injury by the underlying disease process, particularly in cases of trauma. Finally, the lotus petal flap contains hair-bearing skin. However, this is a factor common to all locoregional cutaneous flap options and has not proven problematic in our case series thus far. In our series we have used perforator flaps based on the pudendal artery system. However, a number

of perforator and axial-pattern flaps have been described in the perineal region and could theoretically be applied to this technique. Our aim is to apply reconstructive surgical principles to a common urological problem to improve patient outcomes.

We have used the lotus petal flap in primary PU formation, as well as secondary cases after traditional flap techniques have failed and it has subsequently been used successfully at several high-volume urogenital reconstructive centres worldwide. The technique should be considered in patients undergoing perineal urethrostomy that are at high risk for failure, including revision cases, those that are anticipated to require larger amounts of tissue to prevent excessive wound tension (such as obese patients or those requiring more extensive proximal urethral resection), and patients with local or systemic factors predisposing to wound healing problems (such as prior irradiation, diabetics, smokers, or immunosuppressed patients).

We do not suggest that this technique should be applied to all patients undergoing PU; in the majority of cases, traditional techniques are safe and reliable. Our technique renders the procedure more reliable in high-risk patients, as well as broadening the indications to include patients that traditionally would not be considered for PU.

## Conclusion

Utilisation of lotus petal flaps in high-risk cases of perineal urethrostomy will lead to significant improvements in patient outcomes. The availability of larger amounts of soft tissue coverage will obviate the need for compromise on either resection of involved urethra, or calibre and inset of urethrostomy. This will subsequently minimise the rates of failure, and reduce the

Reilly, Sham, Chee and Chauhan

requirement for urinary diversion procedures.

### Conflicts of interest and source of funding

None

*This work has previously been presented at the following meetings:*

- *Société Internationale d'Urologie (SIU) 35th Congress, Melbourne, Australia, October 2015.*
- *Societe Internationale d'Urologie (SIU) 36th Congress, Buenos Aires, Argentina, October 2016.*
- *7th International Meeting of Reconstructive Urology (IMORU), Hamburg, Germany, March 2016.*
- *Genitourinary Reconstruction (GU-RECON) Live International Symposium, Pune, India, March 2016.*
- *17th International Course on Perforator Flaps, Sydney, Australia, November 2016.*

### References

1. Parker DC, Morey AF, Simhan J. 7-flap perineal urethrostomy. *Transl Androl Urol.* 2015; 4(1): 51-55.
2. Myers JB, McAninch JW. Perineal urethrostomy. *BJU Int.* 2011; 107: 856-865.
3. Barbagli G, De Angelis M, Romano G, Lazzeri M. Clinical outcome and quality of life assessment in patients treated with perineal urethrostomy for anterior urethral stricture disease. *J Urol.* 2009; 182: 548-557.
4. Johanson B. The reconstruction in stenosis of the male urethra (German). *Z Urol.* 1953; 46: 361-375.
5. Blandy JP, Singh M, Tresidder GC. Urethroplasty by scrotal flap for long urethral strictures. *Br J Urol.* 1968; 40: 261-267.
6. Lumen N, Beysens M, Van Praet C, *et al.* Perineal urethrostomy: Surgical and functional evaluation of two techniques. *BioMed Res Int.* 2015.
7. Myers JB, Porten SP, McAninch JW. The outcomes of perineal urethrostomy with preservation of the dorsal urethral plate and urethral blood supply. *Urol.* 2011; 77(5): 1223-1227.
8. Kulkarni S, Barbagli G, Kirpekar D, Mirri F, Lazzeri M. Lichen sclerosus of the male genitalia and urethra: surgical options and results in a multicenter international experience with 215 patients. *Eur Urol.* 2009; 55: 945-954.
9. Lumen N, Houtmeyers P, Monstrey S, Spinoit A-F, Oosterlinck W, Hoebeke P. Revision of perineal urethrostomy using a meshed split-thickness skin graft. *Case Rep Nephrol Urol.* 2014; 4: 12-17.
10. French D, Hudak SJ, Morey AF. The '7-flap' perineal urethrostomy. *Urol.* 2011; 77(6): 1487-1490.
11. Palminteri E, Lazzeri M, Guazzoni G, Turini D, Barbagli G. New 2 stage buccal mucosa graft urethroplasty. *J Urol.* 2002; 167: 130-132.
12. Kamat N. Perineal urethrostomy stenosis repair with buccal mucosa: description of technique and report of four cases. *Urol.* 2008; 72(5): 1153-1155.
13. Salgado CJ, Chim H, Skowronski PP, Oeltjen JO, Rodriguez M, Mardini S. Reconstruction of acquired defects of the vagina and perineum. *Semin Plast Surg.* 2011; 25(2): 155-162.
14. Kim JT, Ho SY, Hwang JH, Lee JH. Perineal perforator-based island flaps: the next frontier in perineal reconstruction. *Plast Reconstr Surg.* 2014; 133(5): 683e-687e.
15. Yii NW, Niranjana NS. Lotus petal flaps in vulvo-vaginal reconstruction. *Br J Plast Surg.* 1996; 49: 547-554.

Reilly, Sham, Chee and Chauhan

16. Niranjan NS. Perforator flaps for perineal reconstructions. *Semin Plast Surg.* 2006; 20(2): 133-143.
17. Payne CE, Williams AM, Hart NB. Lotus petal flaps for scrotal reconstruction combined with integra resurfacing of the penis and anterior abdominal wall following necrotising fasciitis. *J Plast Reconstr Aesthet Surg.* 2009; 62: 393-397.
18. Warriar SK, Kimble FW, Blomfield P. Refinements in the lotus petal flap repair of the vulvo-perineum. *ANZ J Surg.* 2004; 74: 684-688.
19. Monstrey S, Blondeel P, Van Landuyt K, Verpaele A, Tonnard P, Matton G. The versatility of the pudendal thigh fasciocutaneous flap used as an island flap. *Plast Reconstr Surg.* 2001; 107(3): 719-725.