

How to do a simple dermabrasion tattoo technique for a single-stage nipple areolar reconstruction

Aisling McNamara MB, BCh, BAO

Fiona Stanley Hospital, Perth, WESTERN AUSTRALIA, AUSTRALIA; St John of God Hospital, Subiaco, Western Australia, AUSTRALIA

Mark Lee MBBS, FRACS(PLAST)

St John of God Hospital, Subiaco, Western Australia, AUSTRALIA; Royal Australasian College of Surgeons Court of Examiners, East Melbourne, Victoria, AUSTRALIA; co-Editor-in-Chief, Australasian Journal of Plastic Surgery, St Leonards, New South Wales, AUSTRALIA.

STEP 1

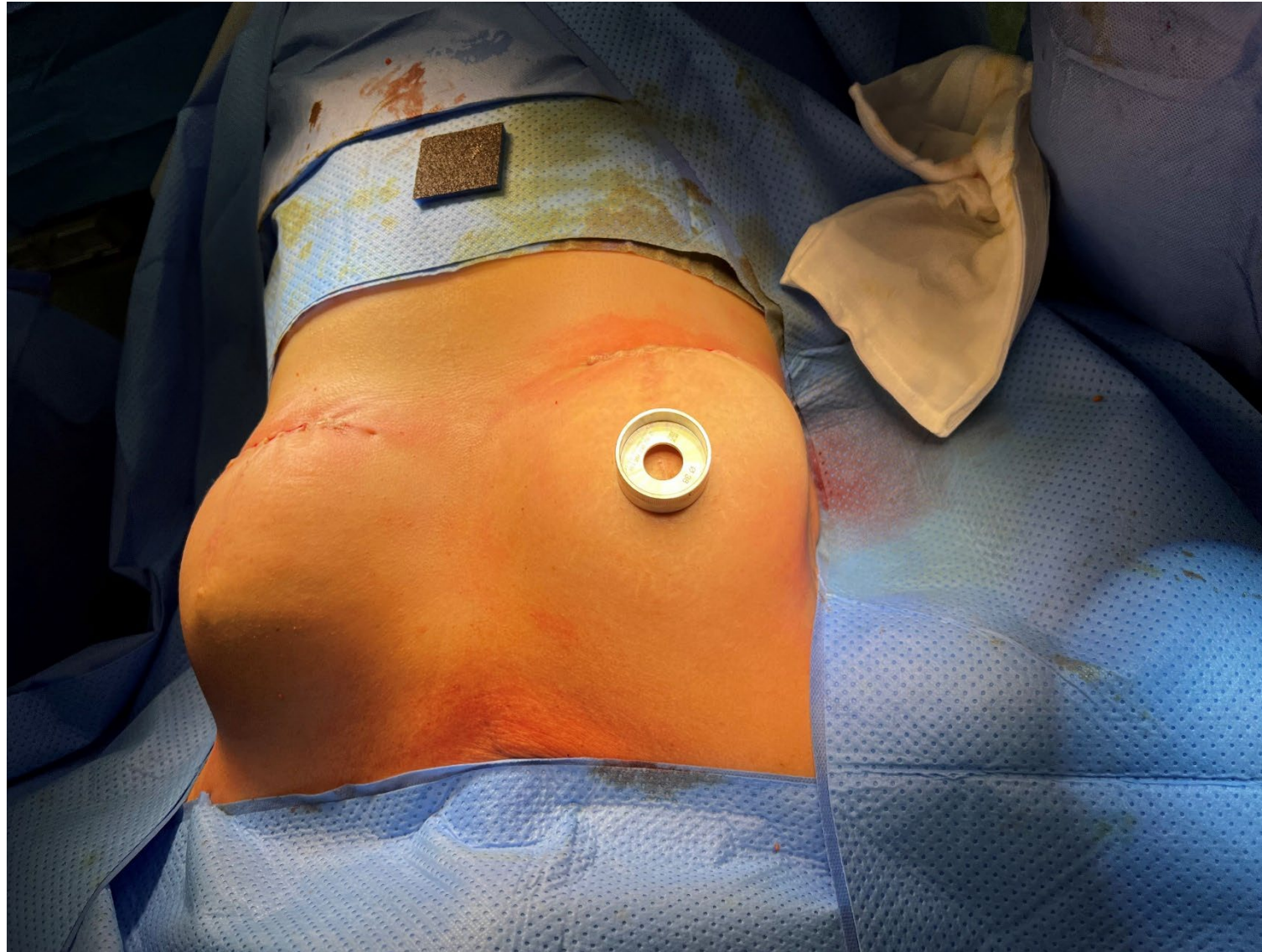


Fig 1. Fig 28. Patient C – 5 years postoperatively

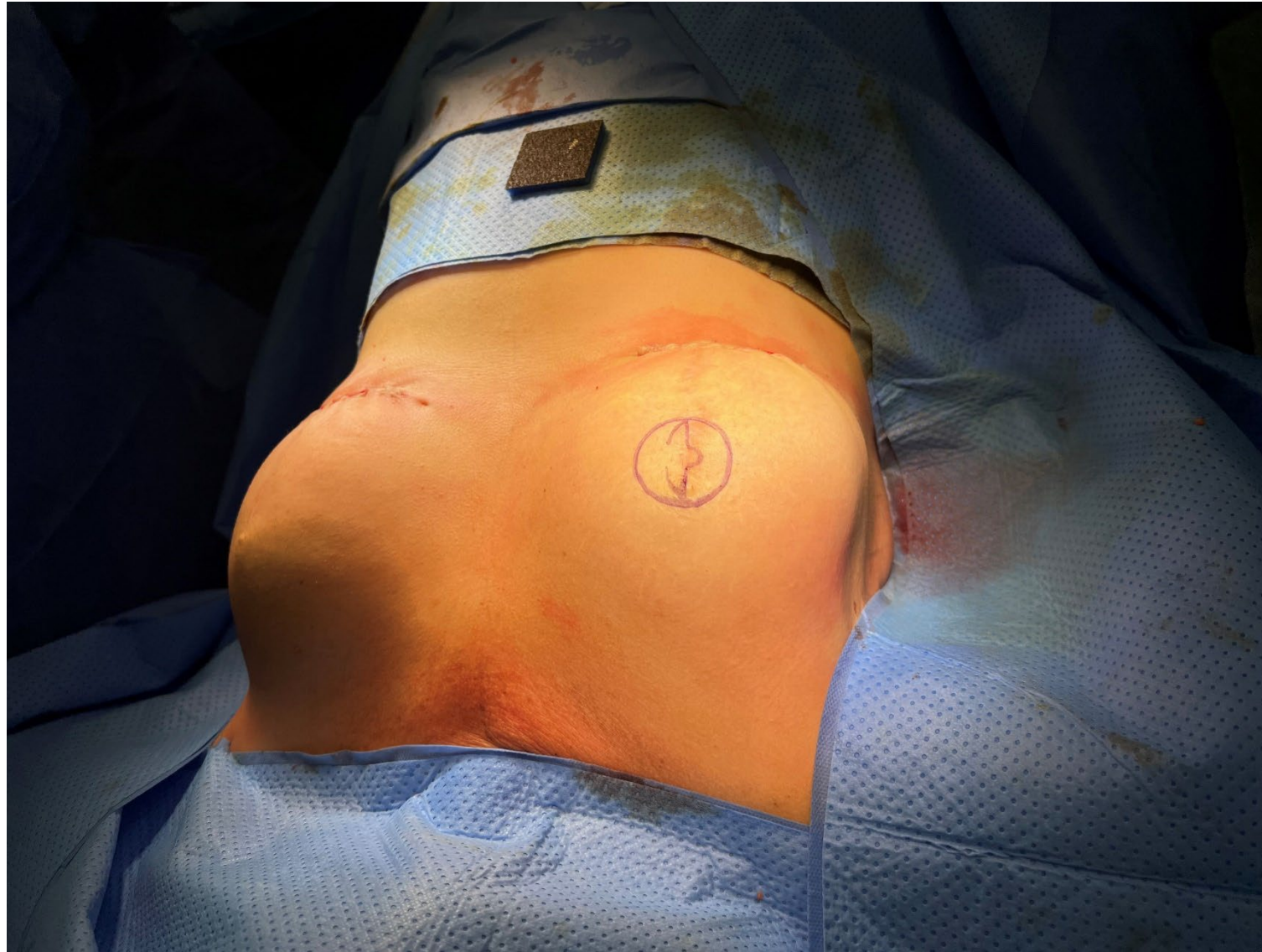

Fig 2. Finished markings of areola

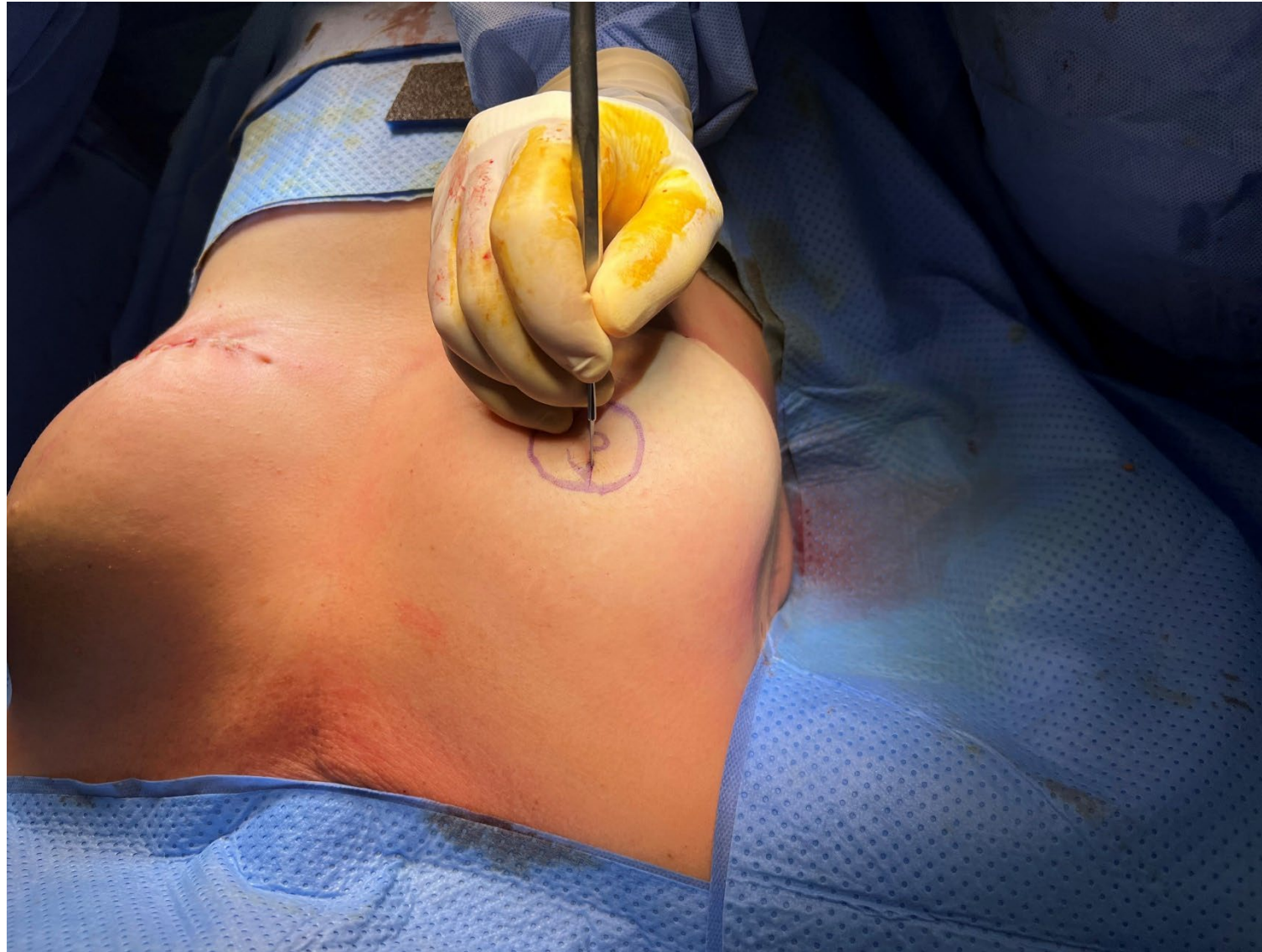

Fig 3. Scoring of flap

STEP 2

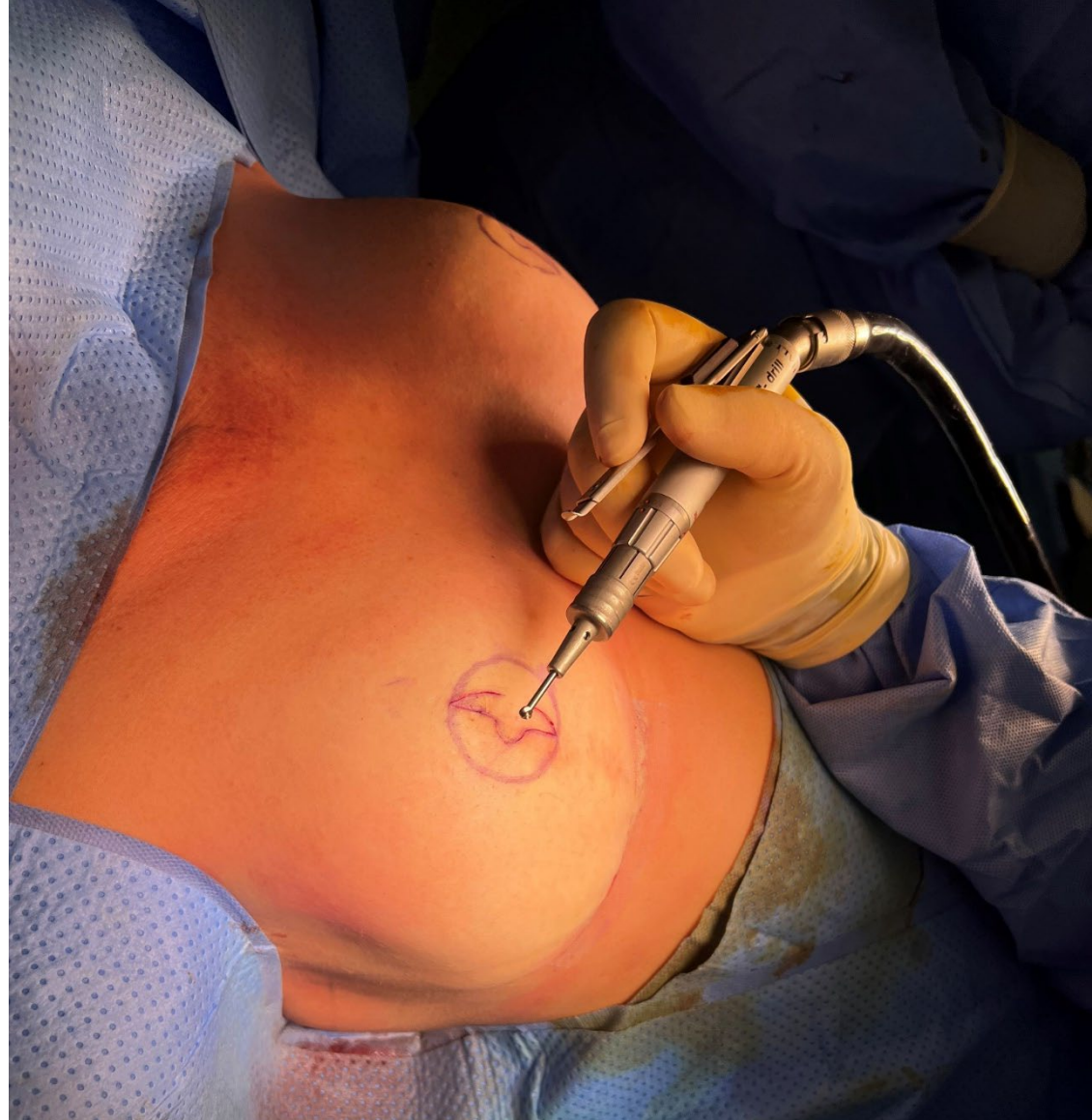

Fig 4. Dermabrasion of areola and flap (a)

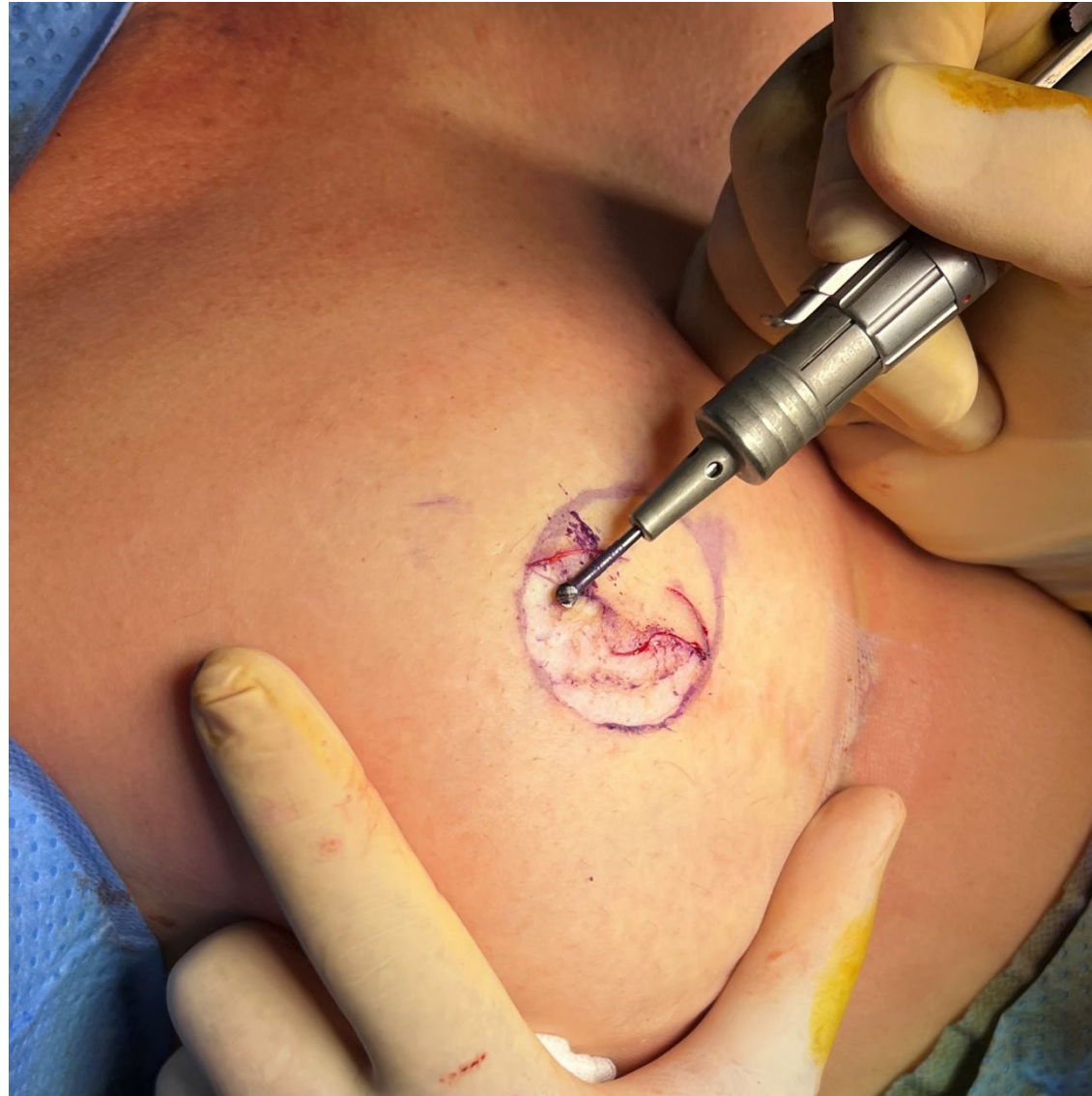

Fig 5. Dermabrasion of areola and flap (b)

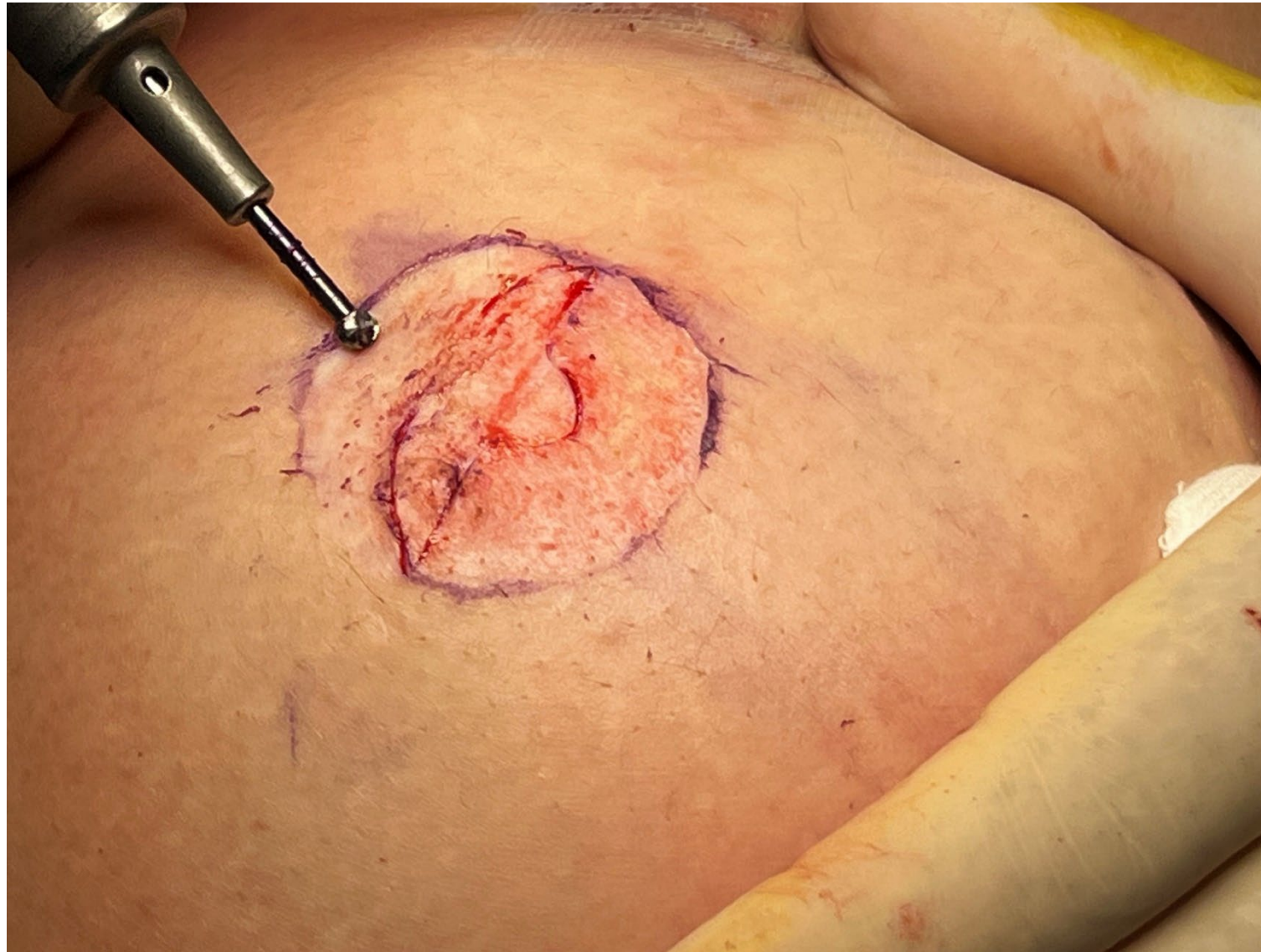

Fig 6. Demonstration of ideal level of punctate bleeding post-dermabrasion

STEP 3

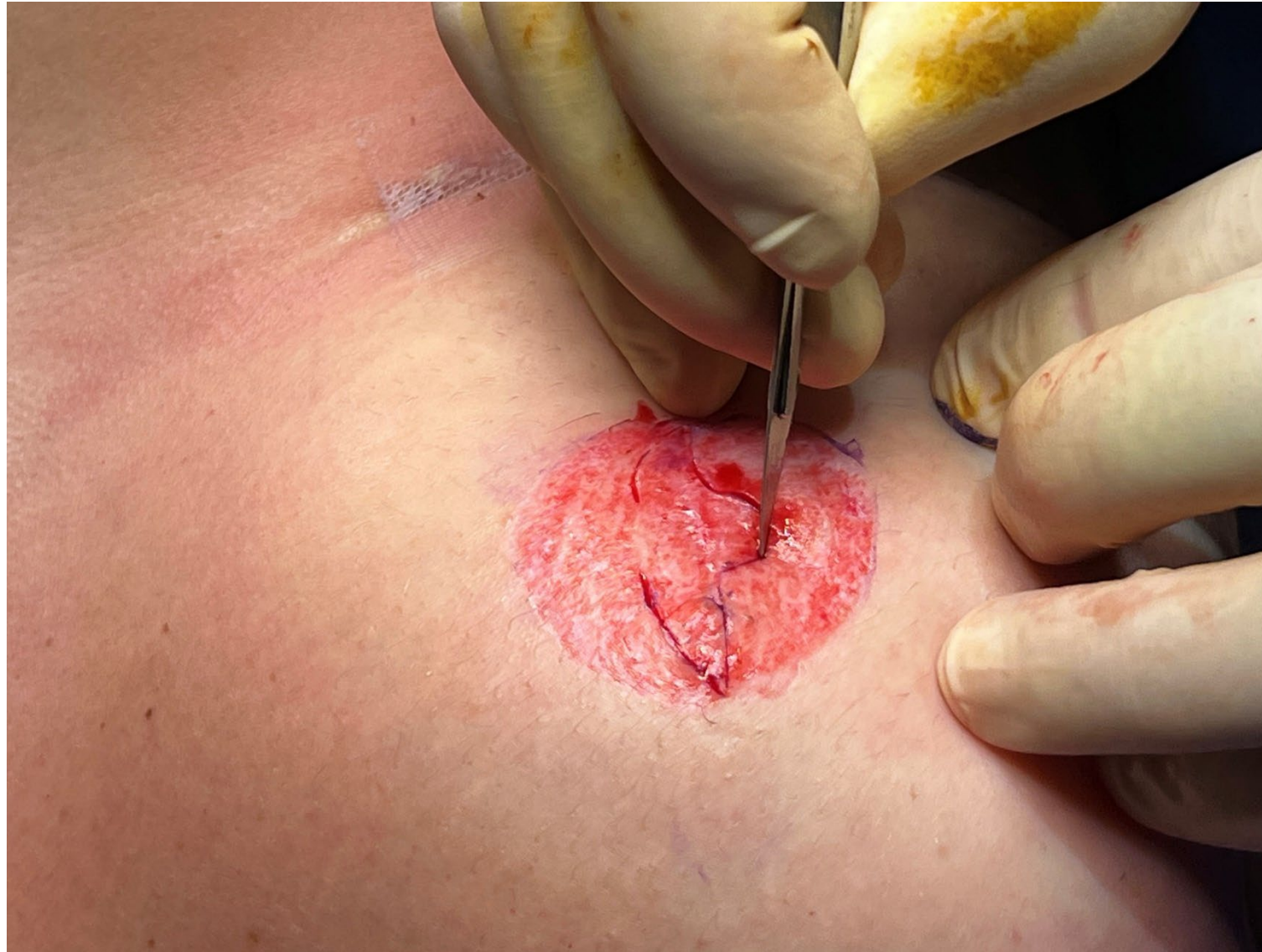

Fig 7. Flap reconstruction – incising flap (a)

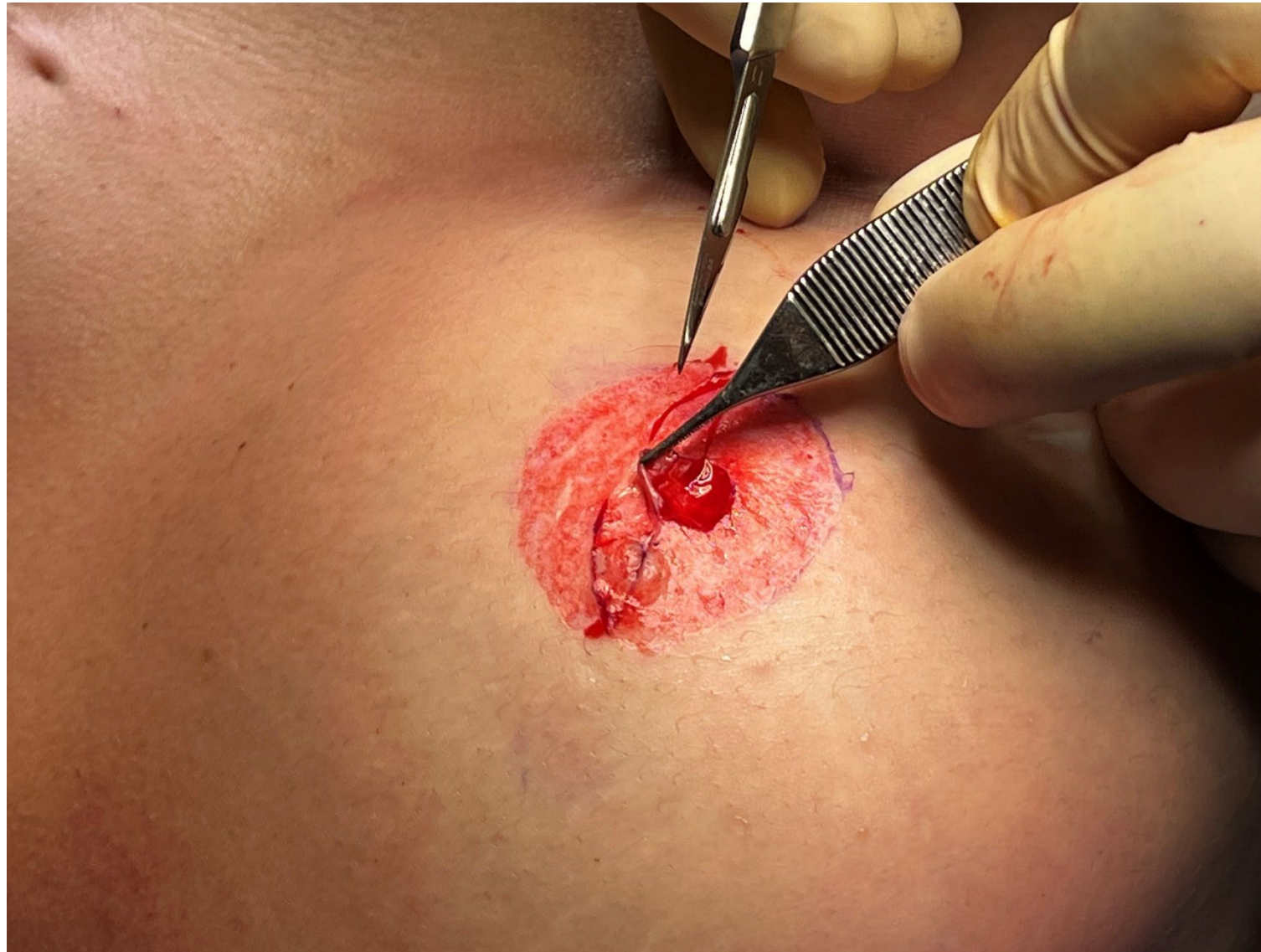

Fig 8. Flap reconstruction – incising flap (b)

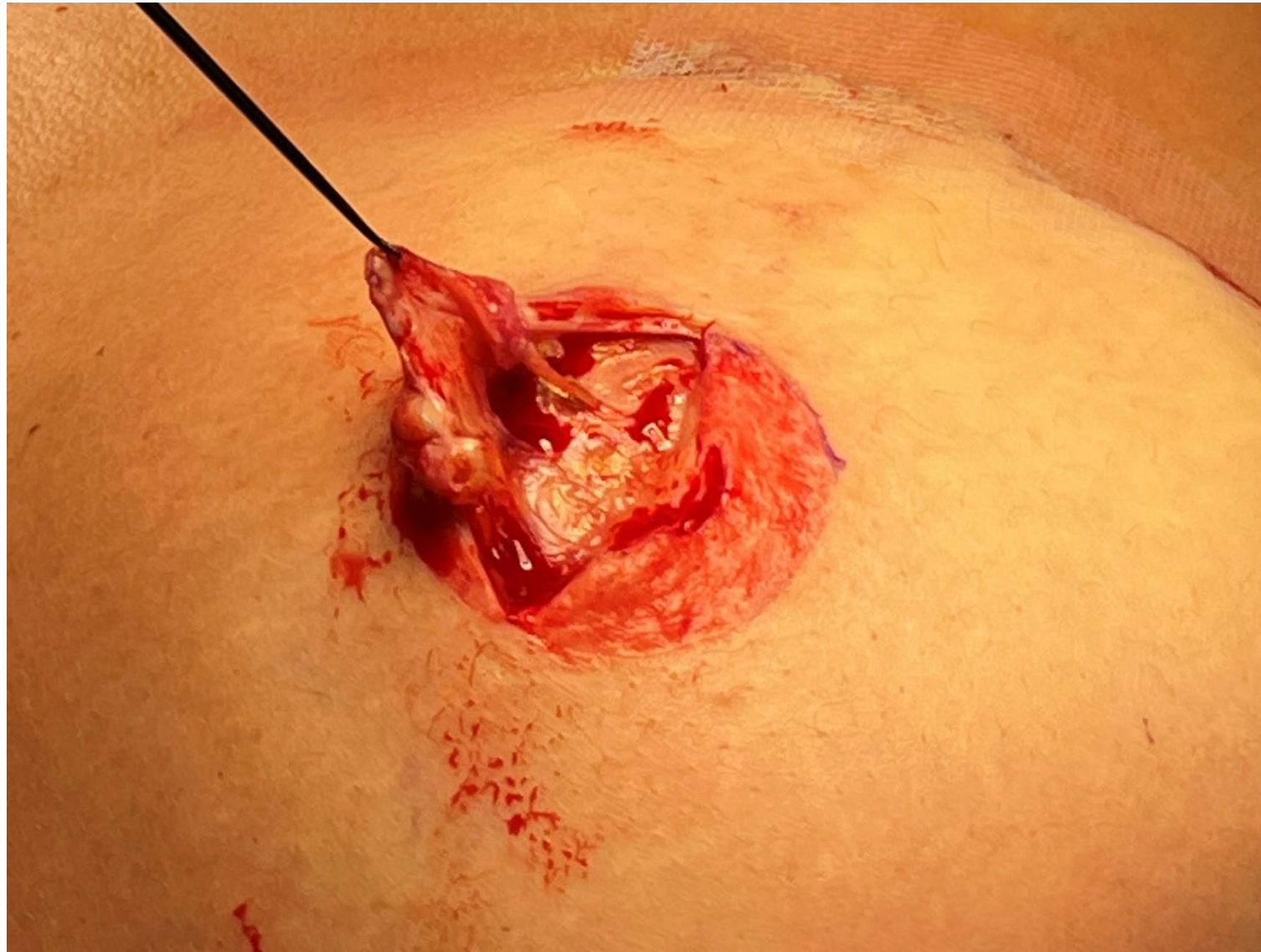

Fig 9. Raising of flap

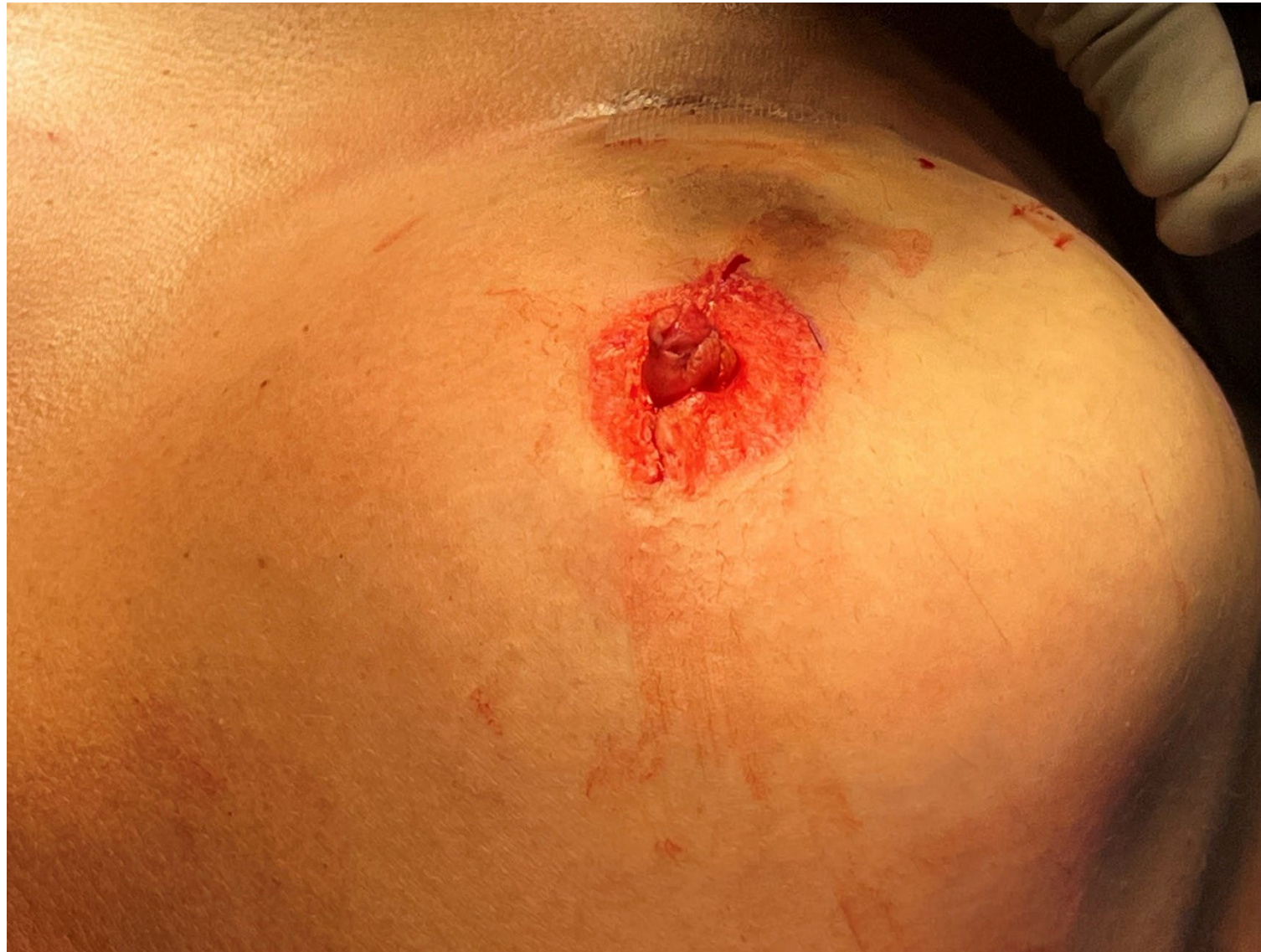

Fig 10. Flap reconstruction

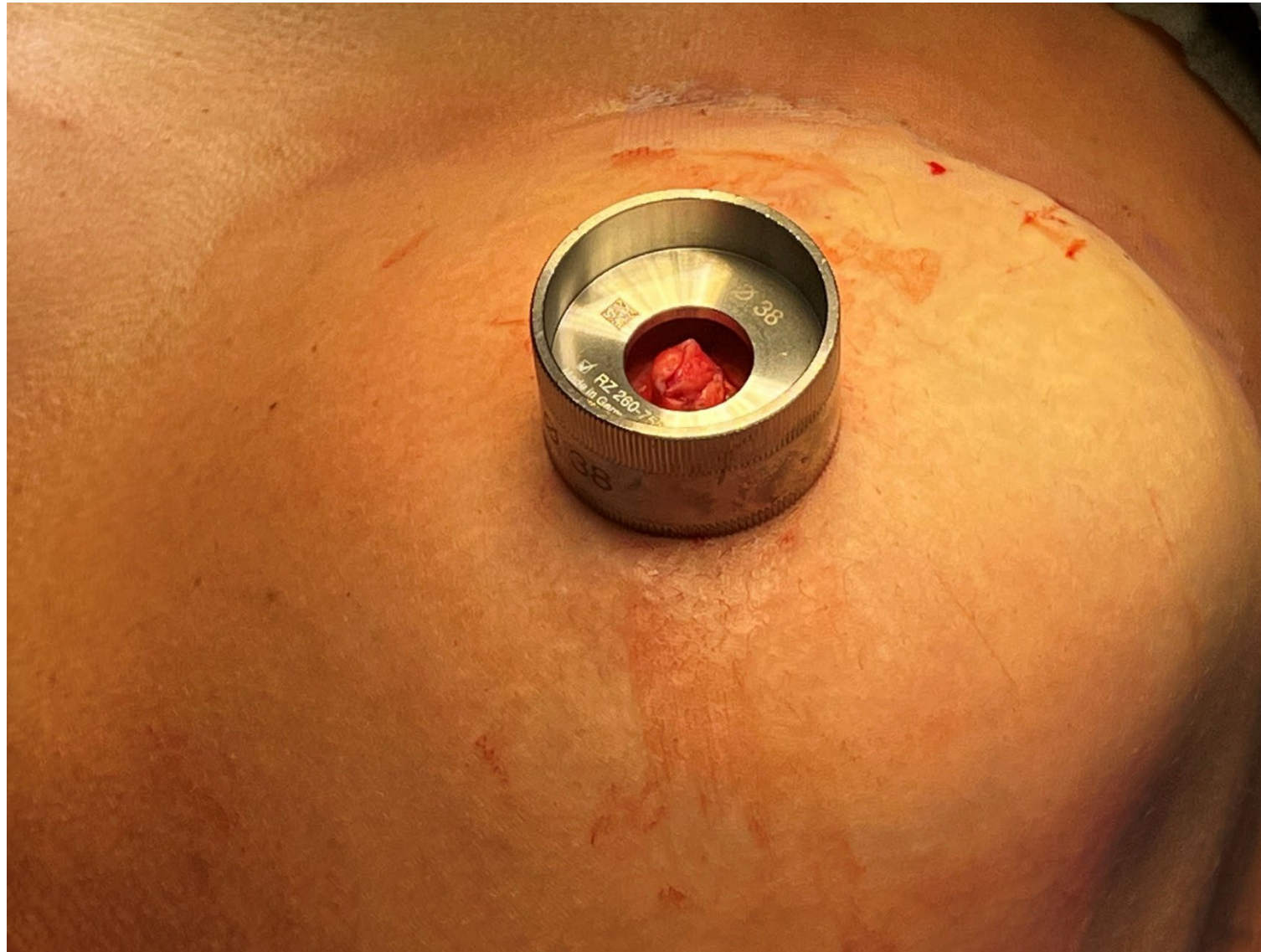

Fig 11. Remarking of areola using areola marker

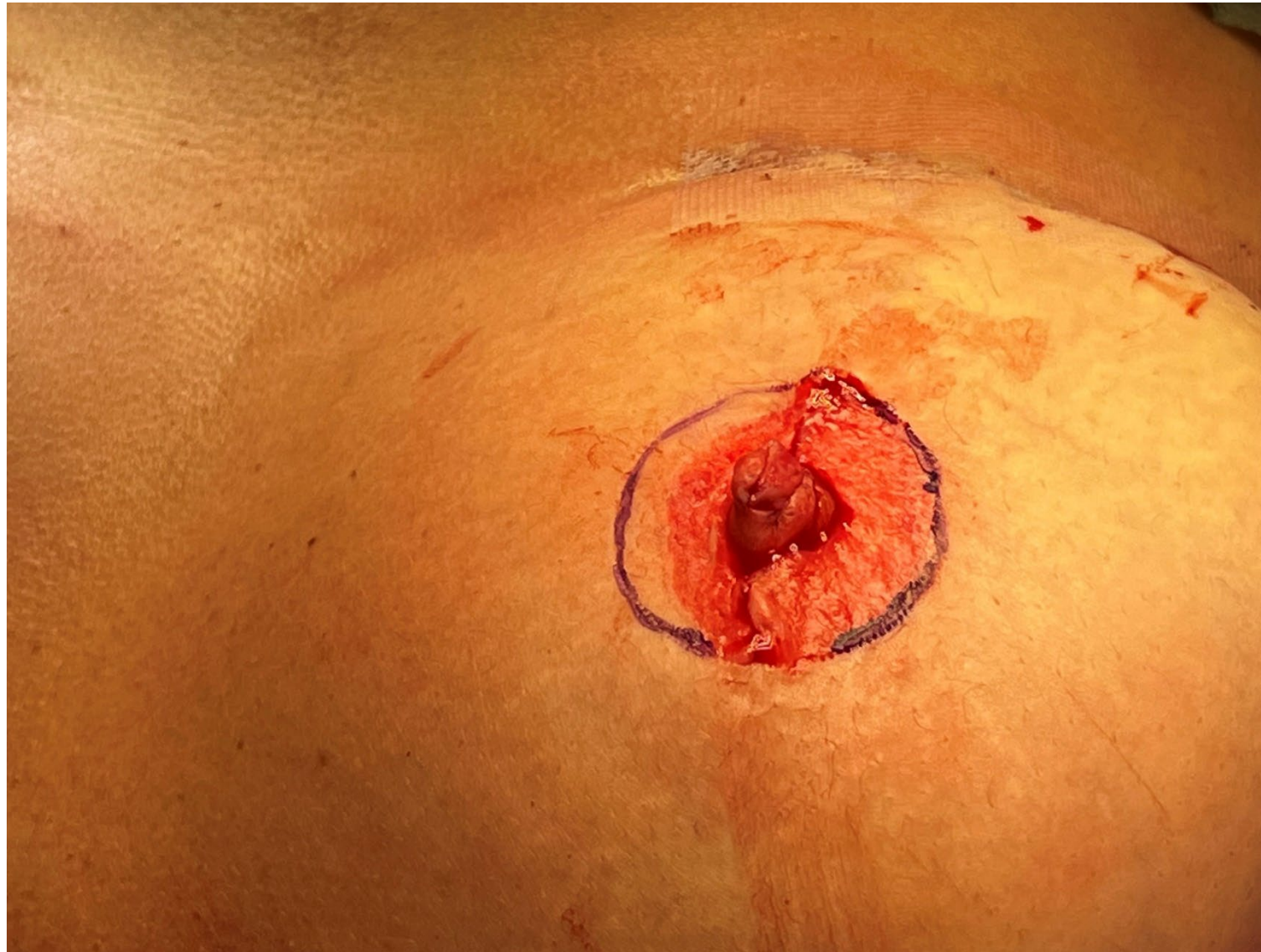

Fig 12. Finished remarking of areola

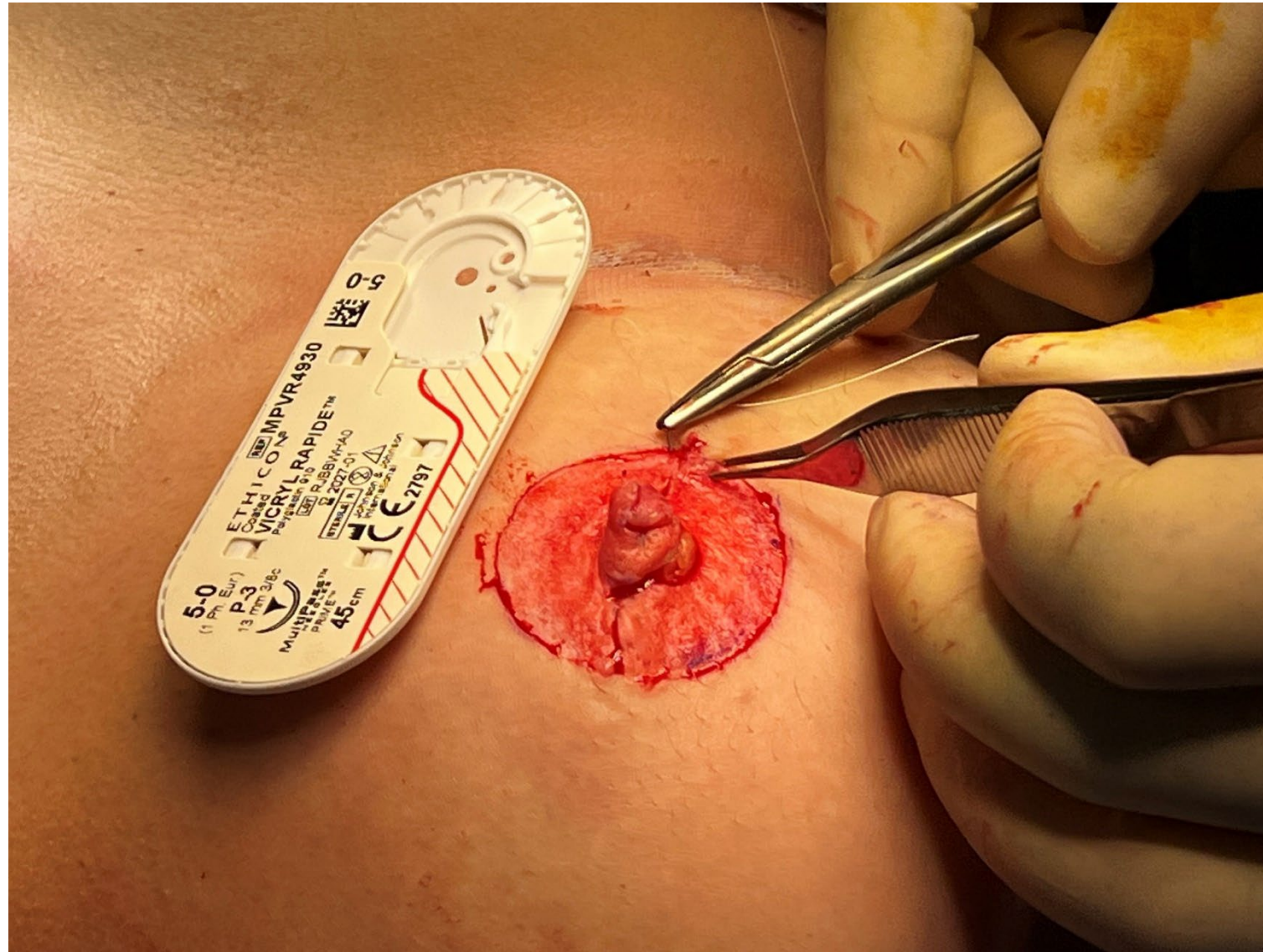


Fig 13. Closure of defect (a)

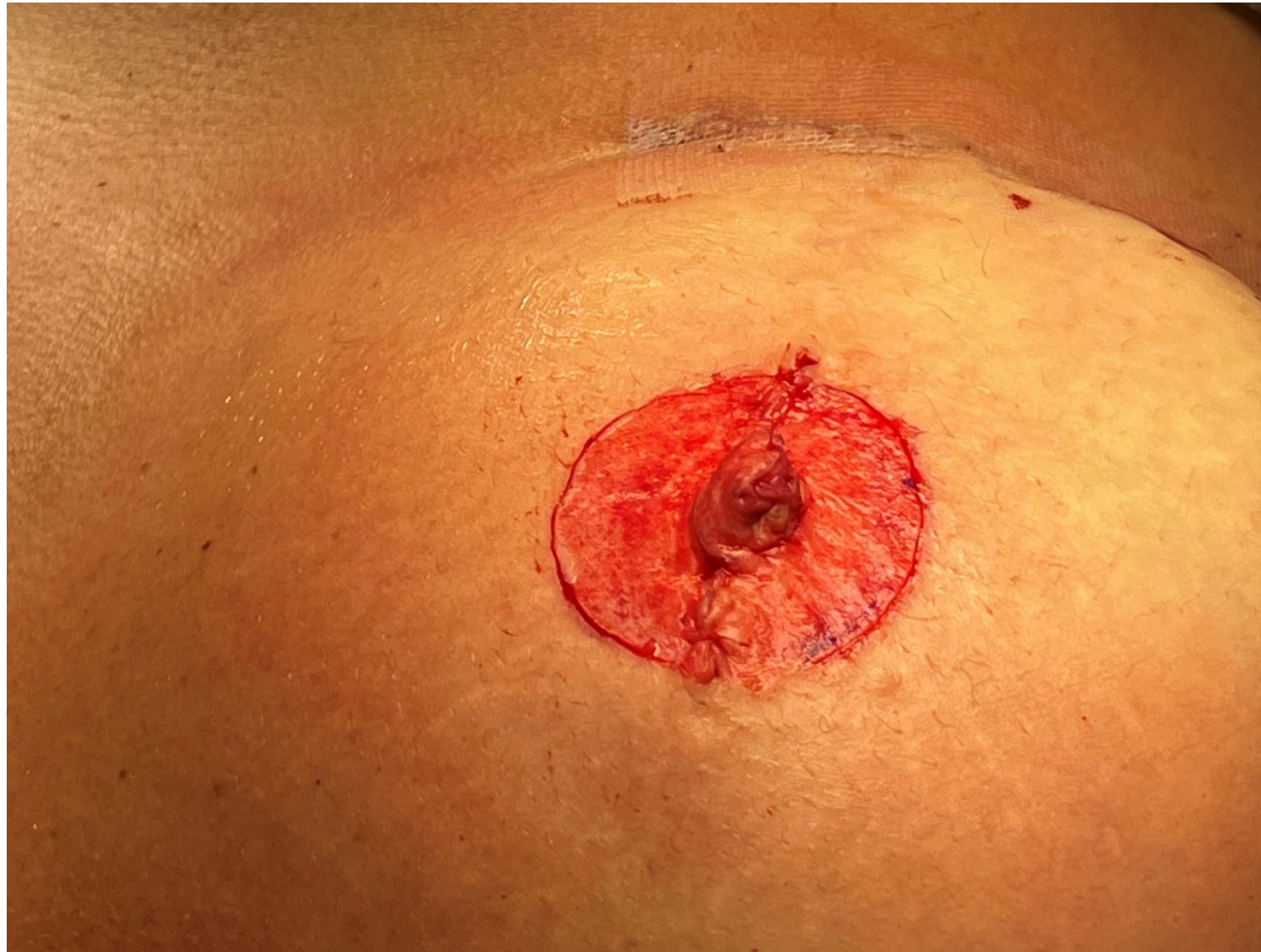

Fig 14. Completed flap reconstruction

STEP 4




Fig 15. Mixing of tattoo inks

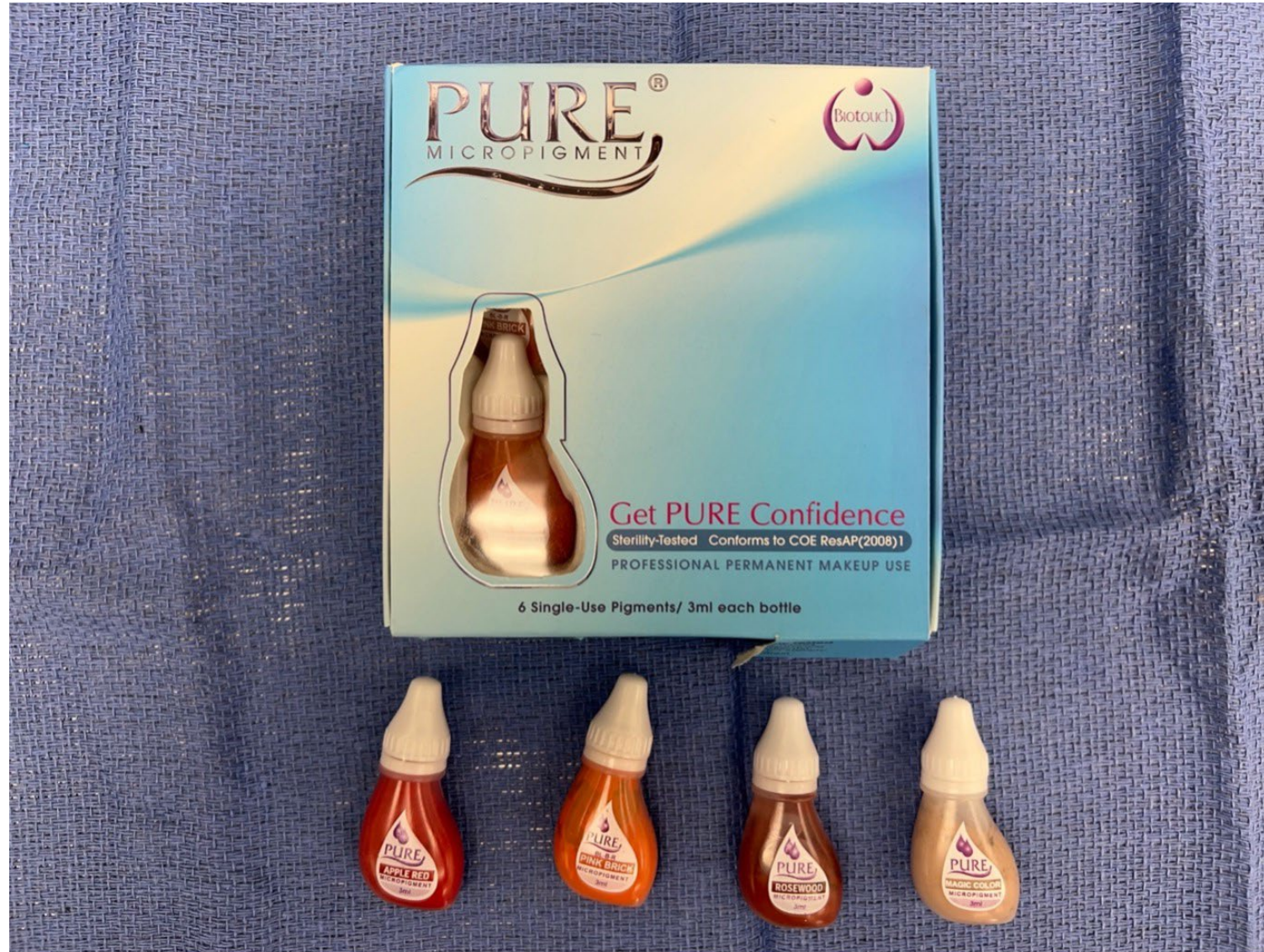

Fig 16. Tattoo inks used

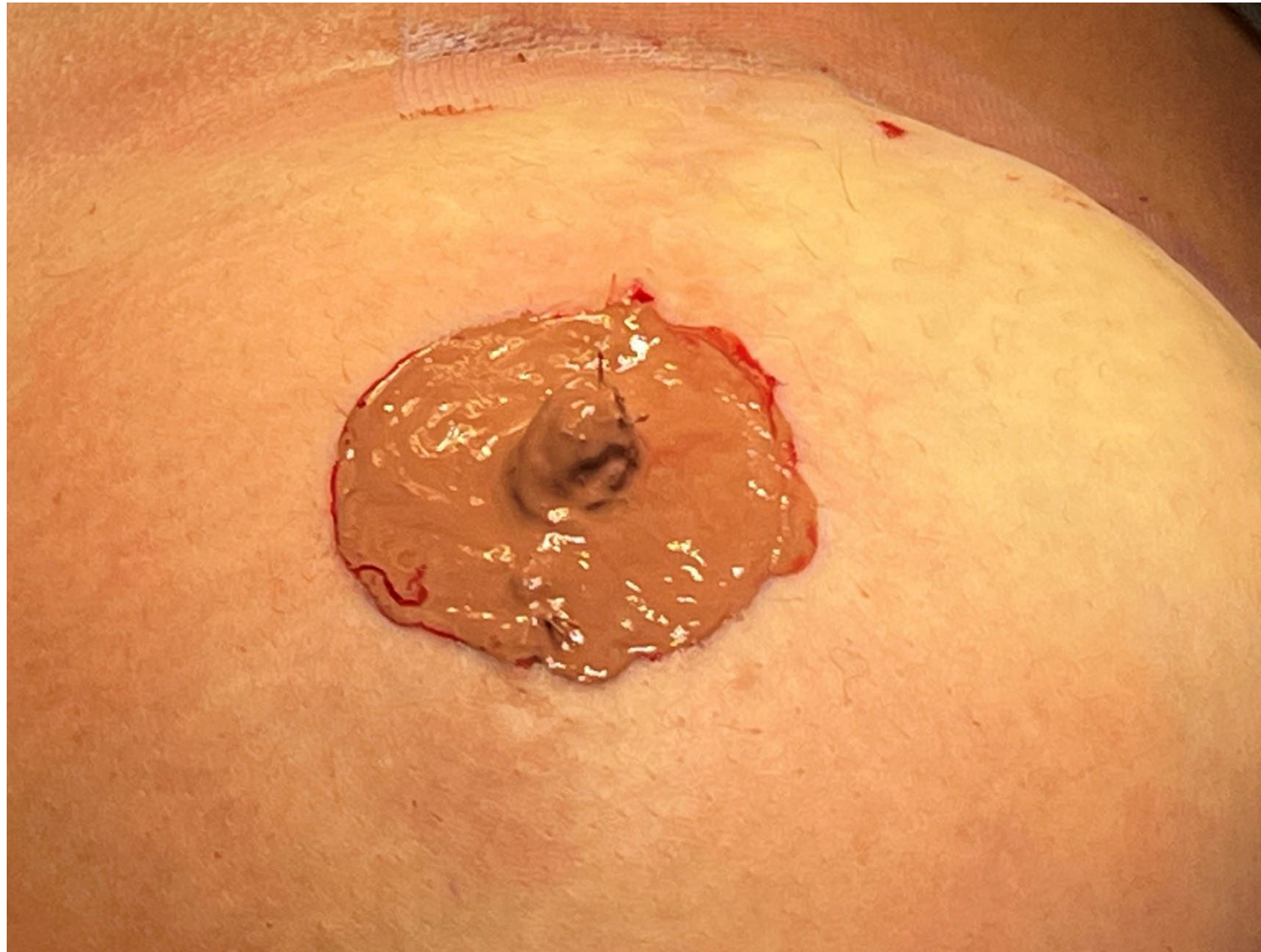

Fig 17. Application of ink

POSTOPERATIVE CARE

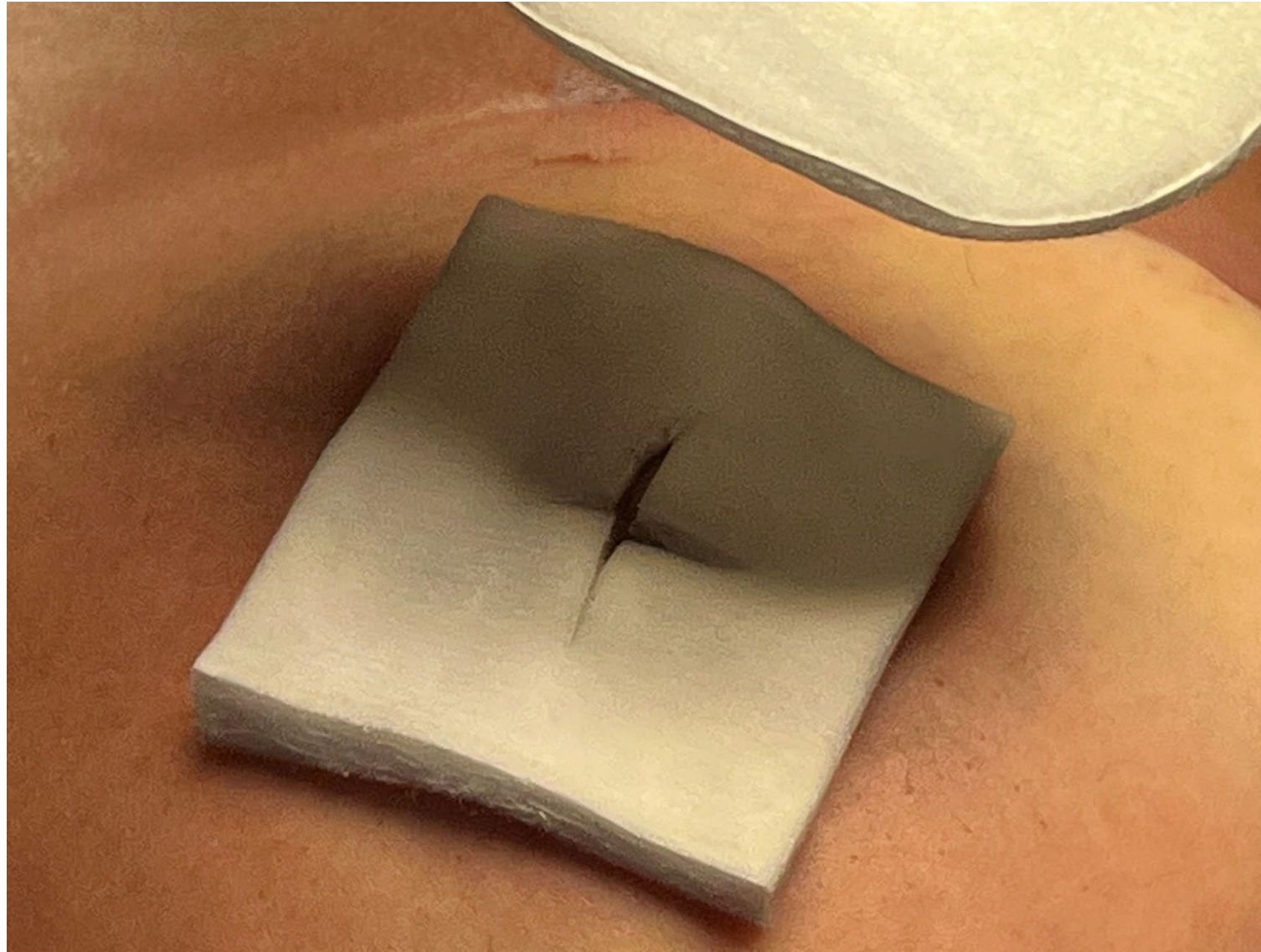


Fig 18. Application of non-adherent dressing

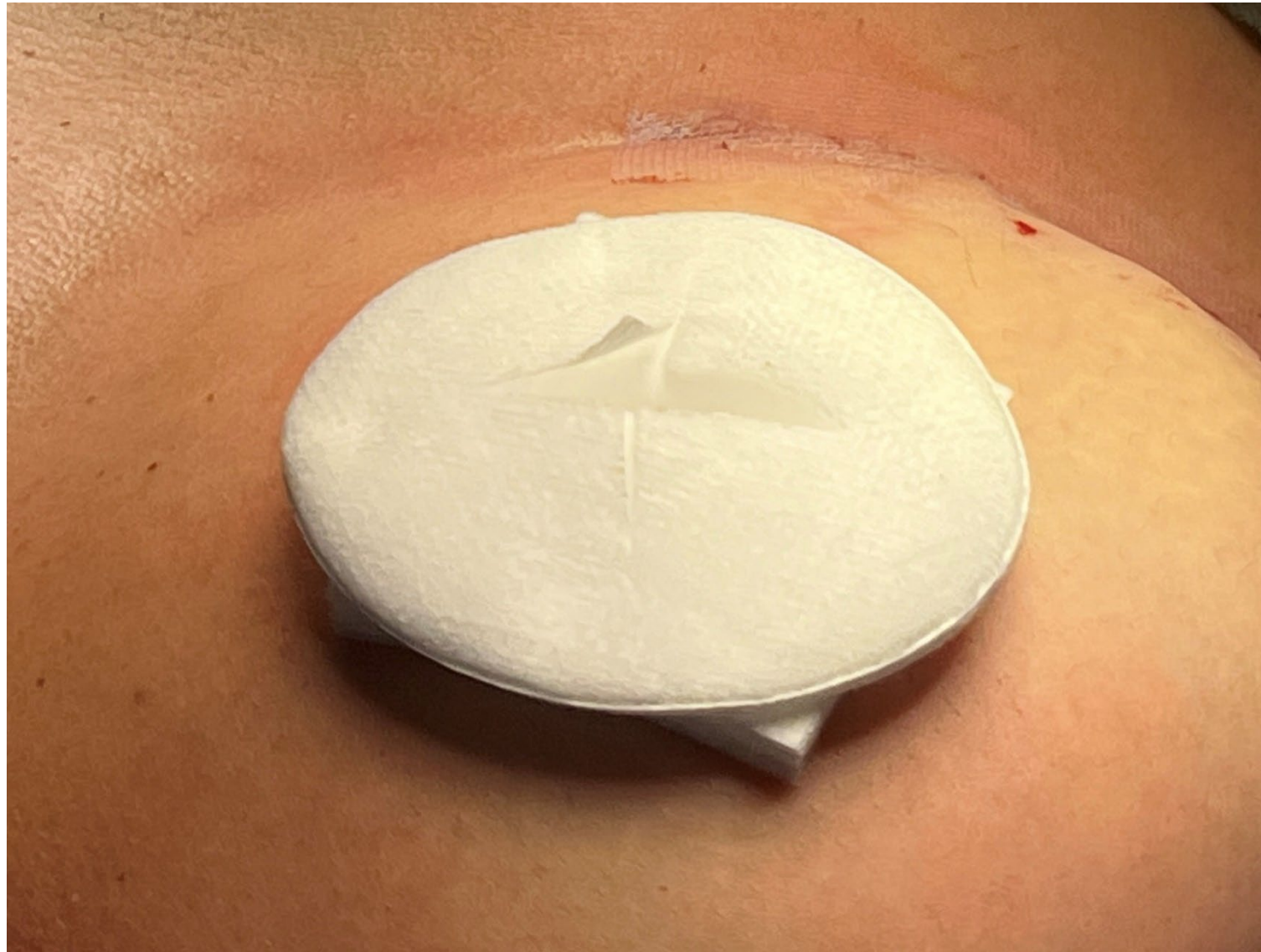

Fig 19. Application of padded dressing

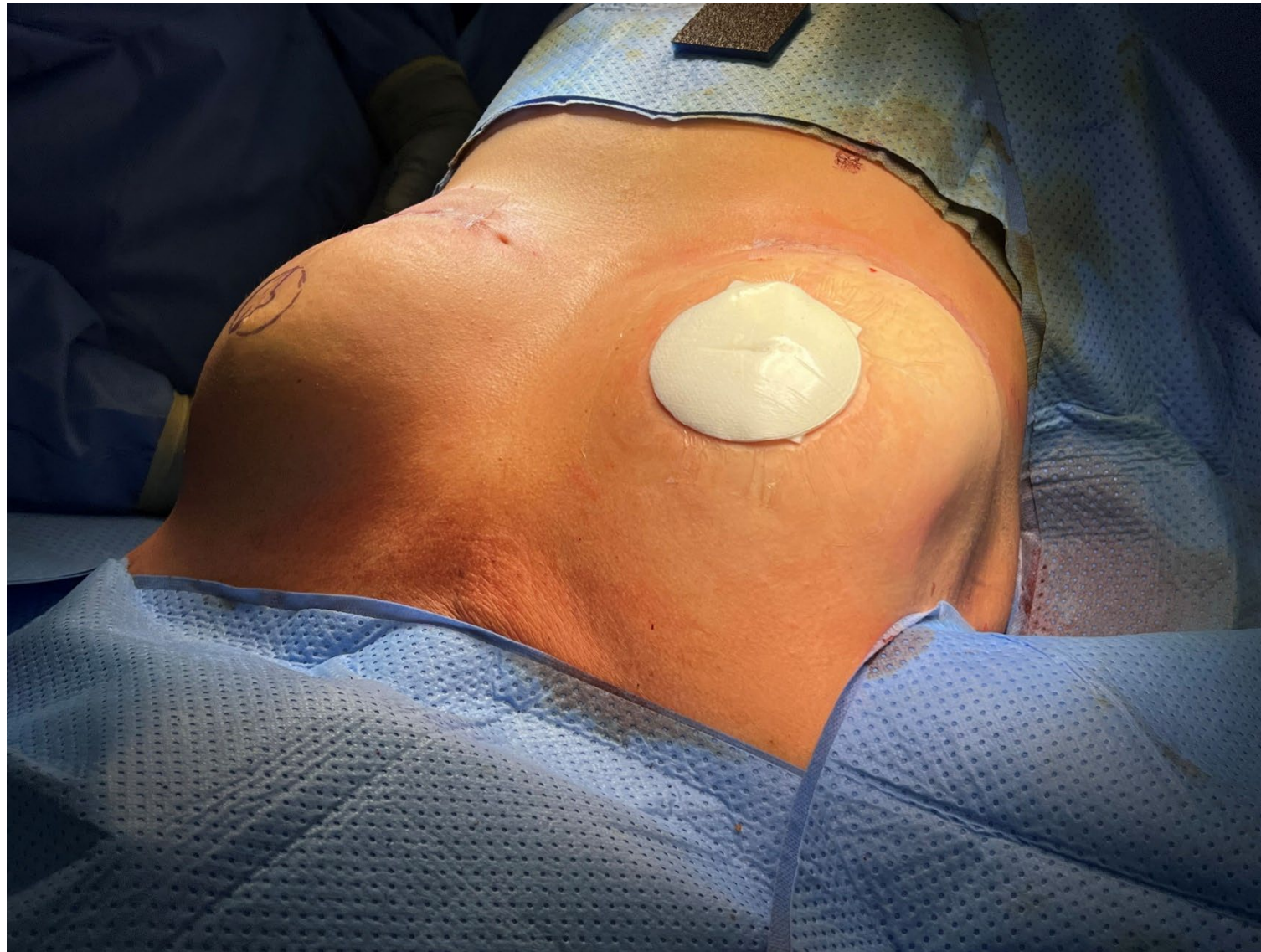

Fig 20. Application of transparent film dressing

**POSTOPERATIVE
RESULTS**

PATIENT A

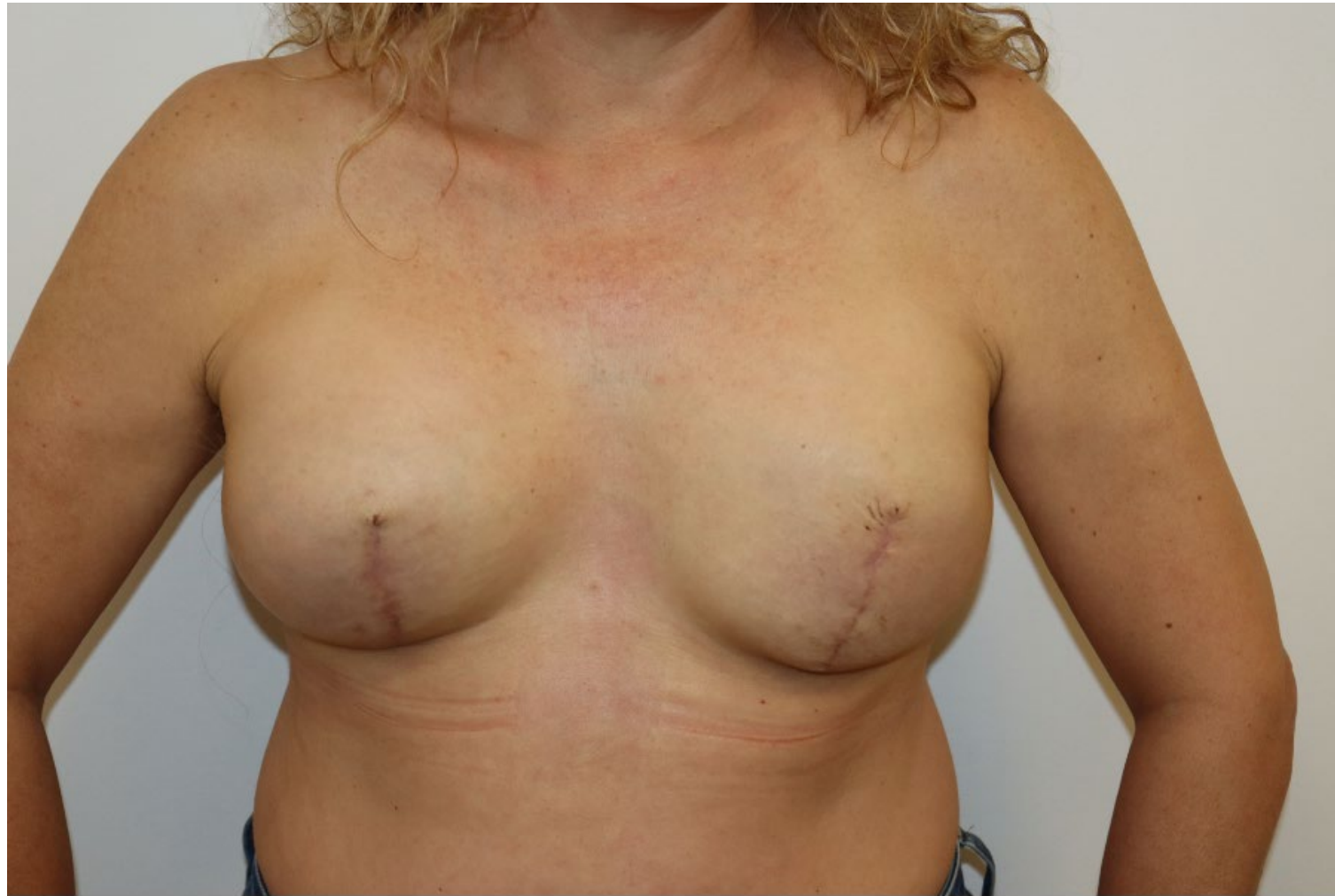

Fig 21. Patient A—preoperatively

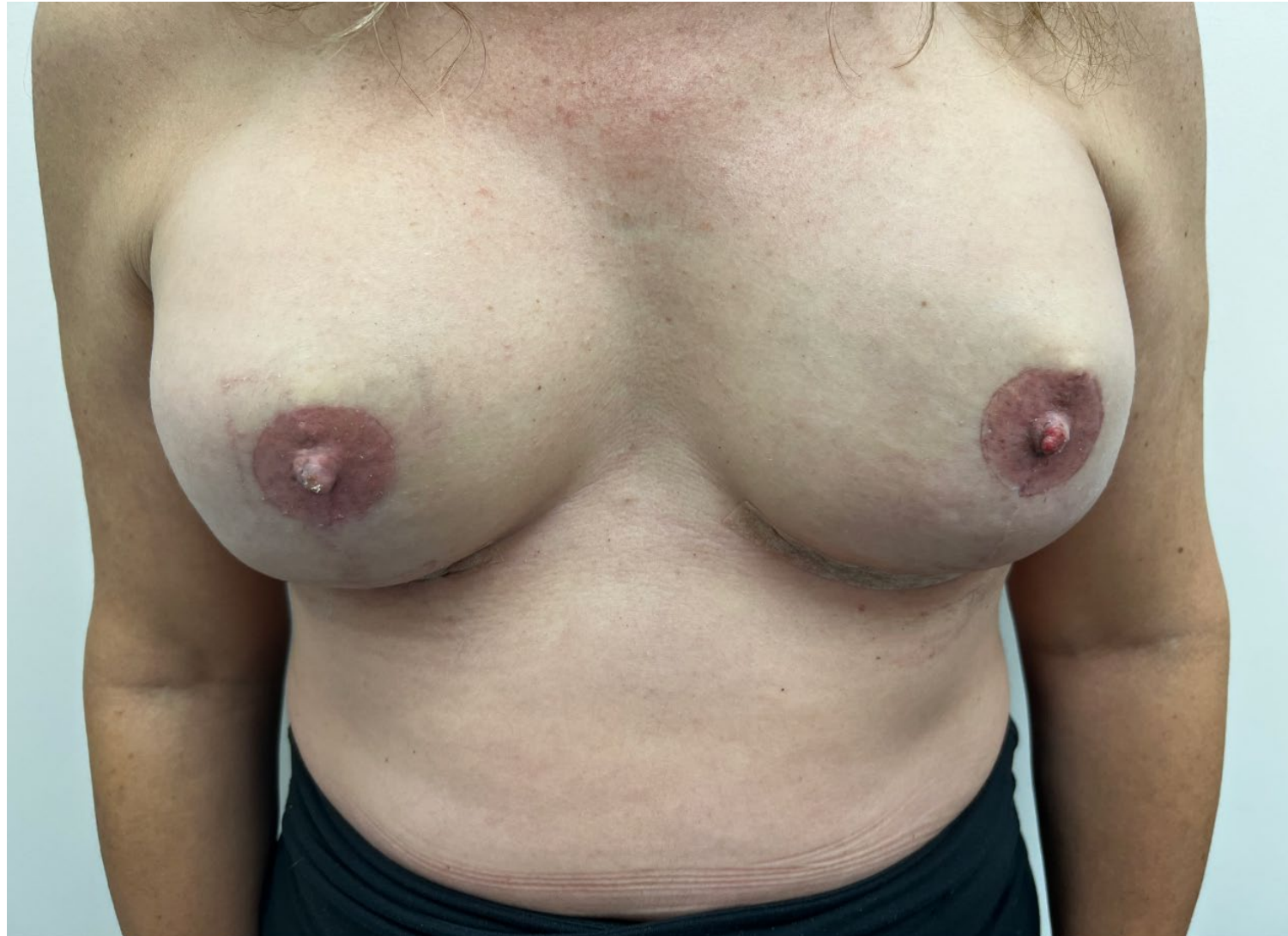

Fig 22. Patient A—6 months postoperatively

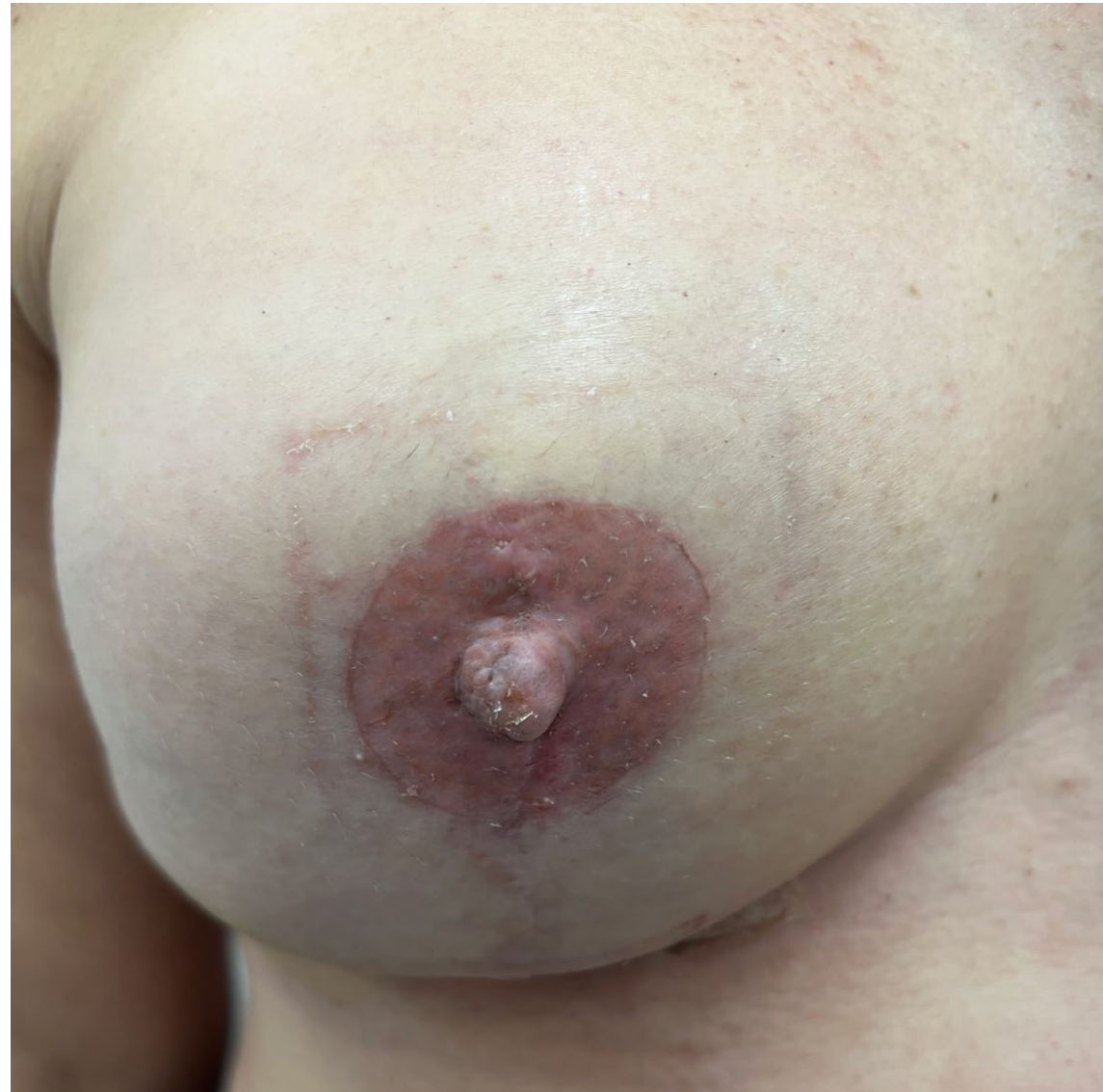

Fig 23. Patient A—6 months postoperatively

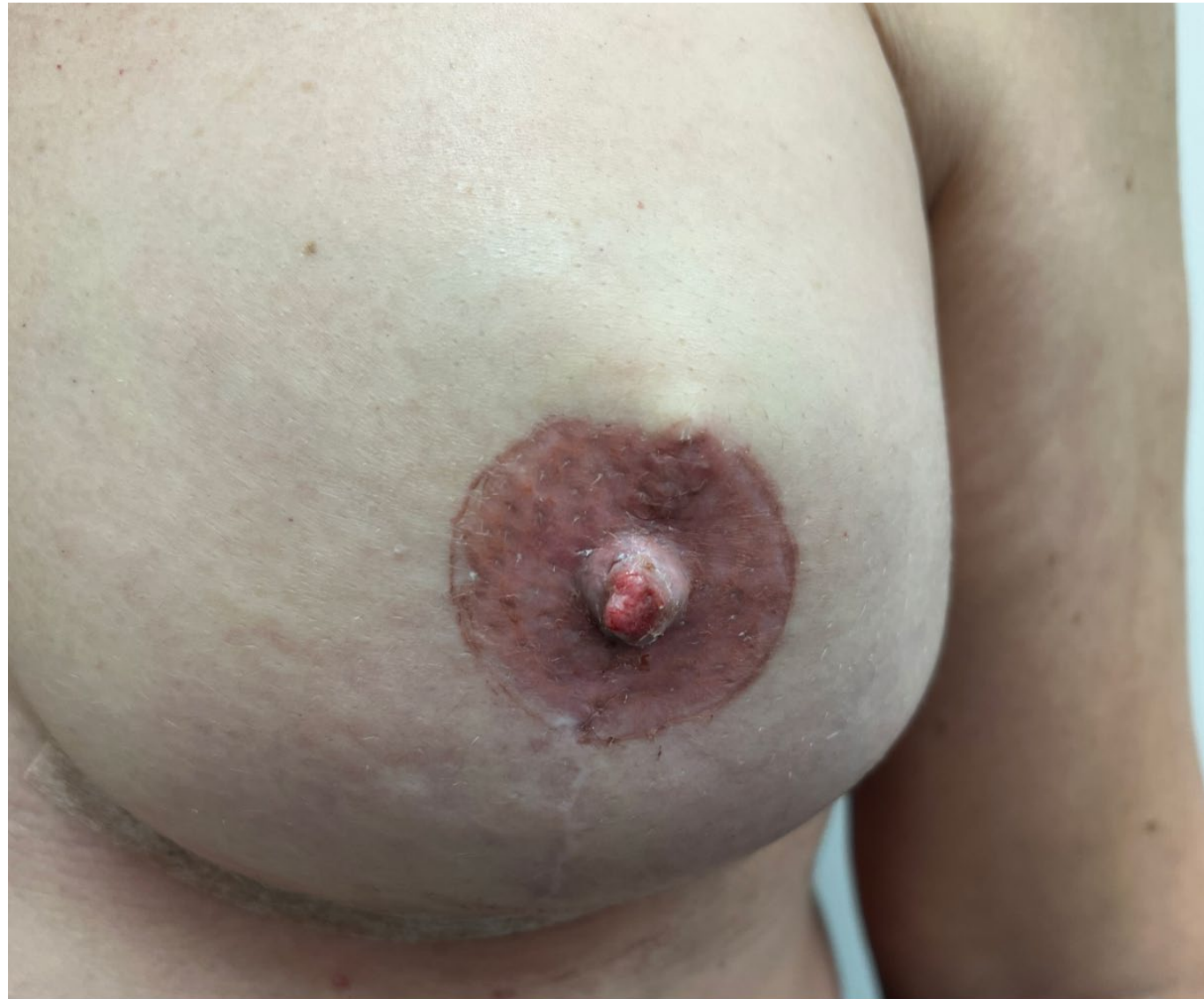

Fig 24. Patient A—6 months postoperatively

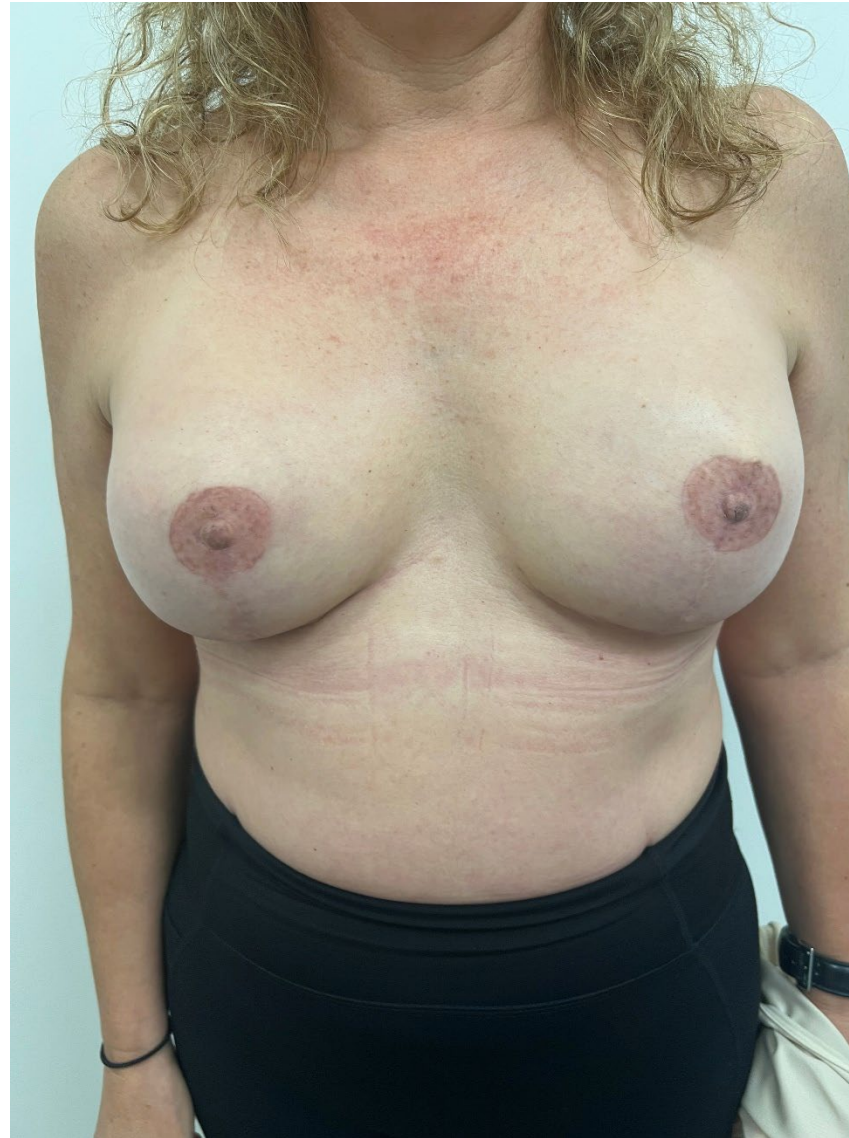

Fig 25. Patient A—6 months postoperatively

**POSTOPERATIVE
RESULTS**

PATIENT B

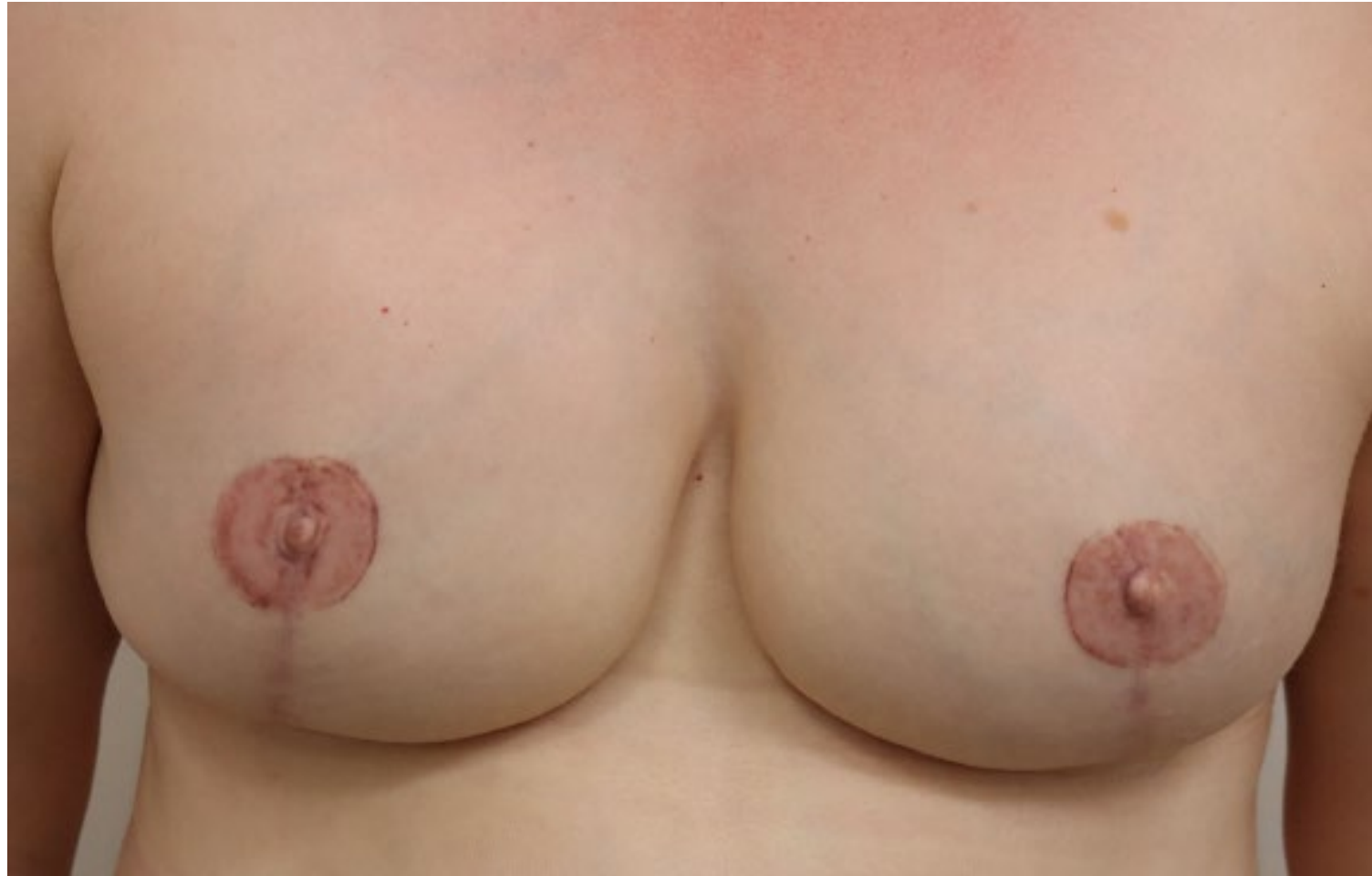

Fig 26. Patient B—2 years postoperatively

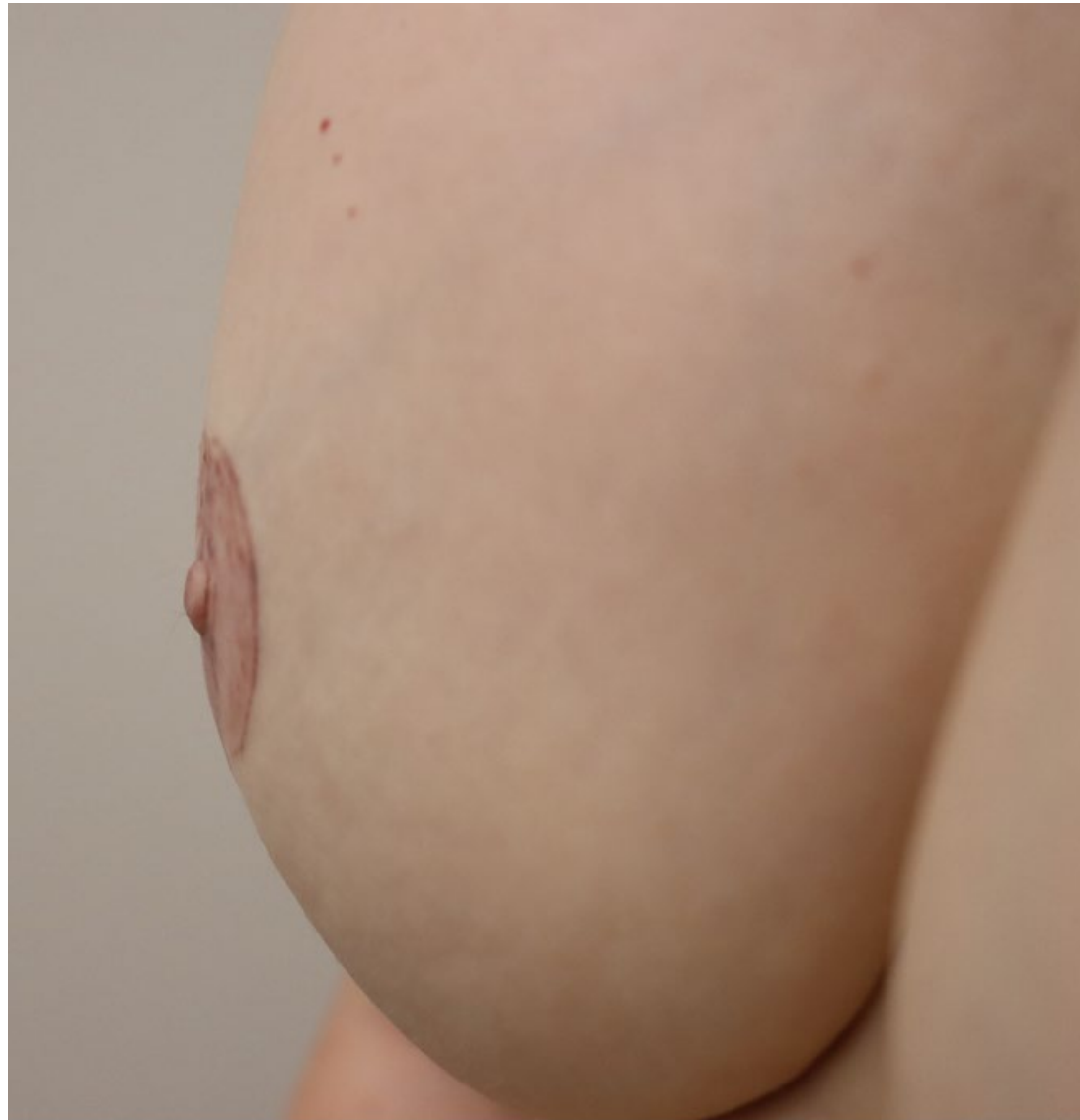

Fig 27. Patient B—2 years postoperatively

**POSTOPERATIVE
RESULTS**

PATIENT C

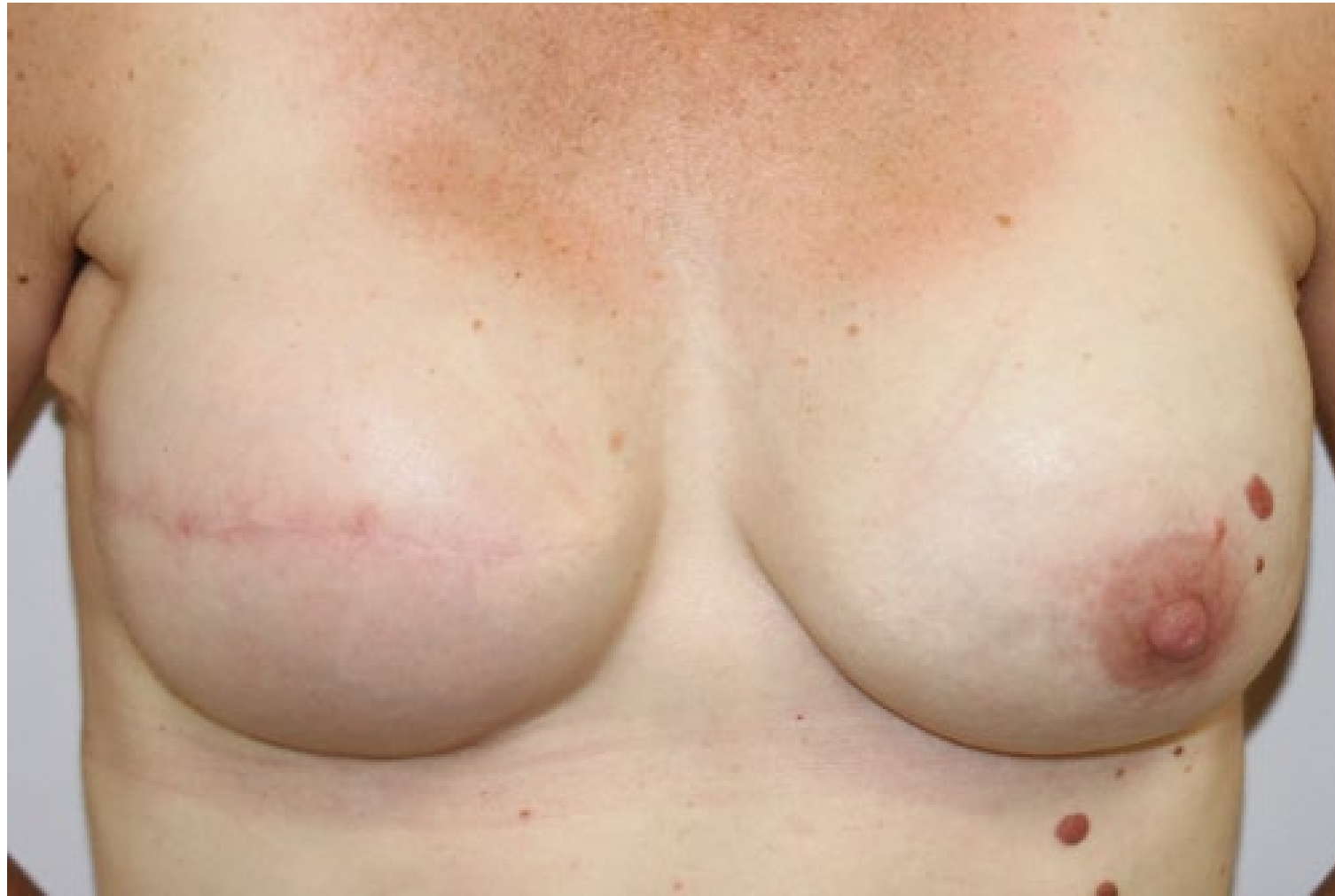

Fig 28. Patient C—preoperatively

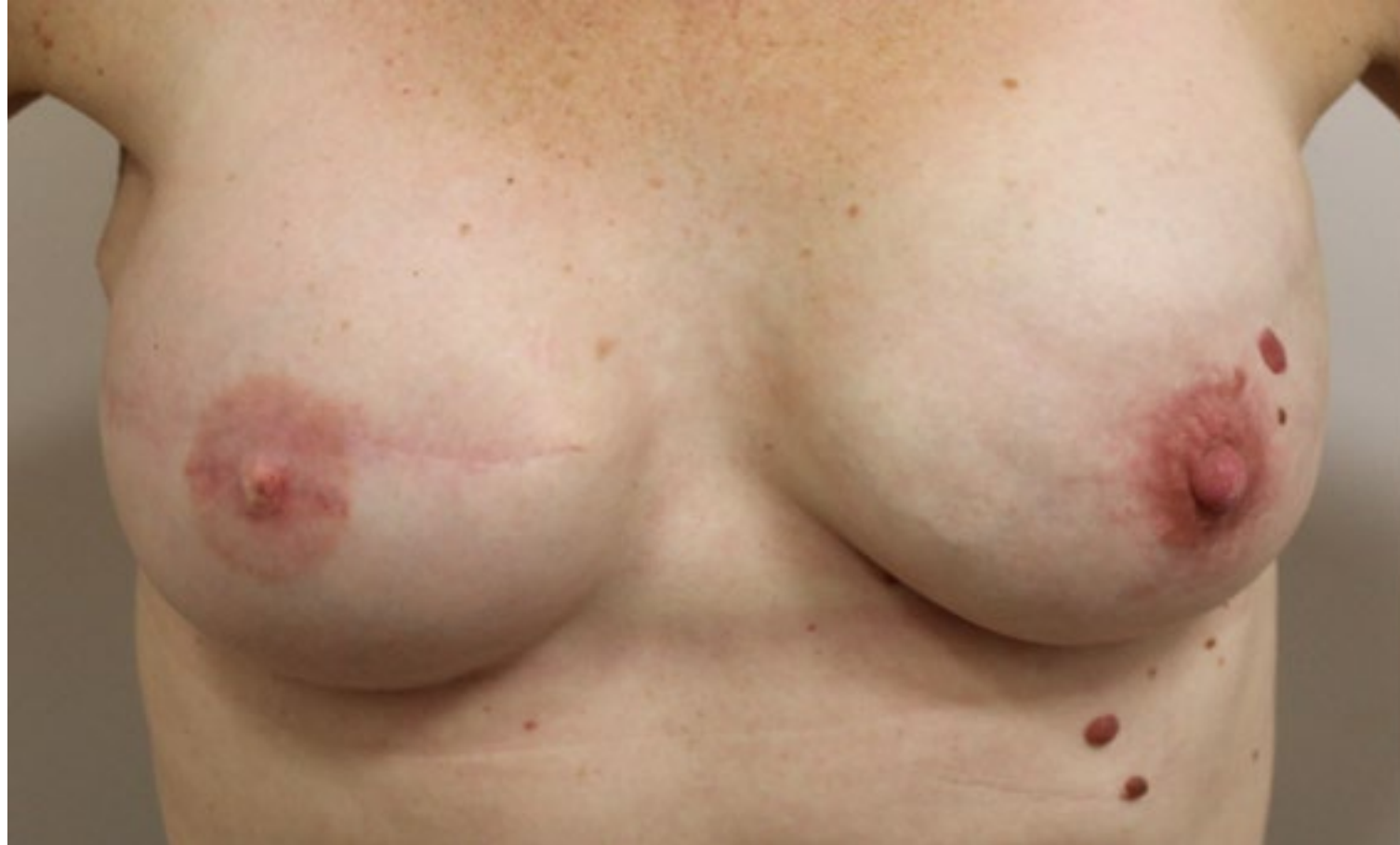

Fig 29. Patient C—5 years postoperatively